



The initial experience of natural orifice specimen extraction surgery in laparoscopic colorectal surgery

Zi Qin Ng, Naradha Lokuhetty, Chloe Macdonald, Satish Warriar

Department of Colorectal Surgery, The Alfred, Melbourne, Australia

ABSTRACT

Natural orifice specimen extraction surgery (NOSE) is an extension of minimally invasive colorectal surgery. NOSE was introduced into the unit in January 2024 in selected group of patients. The aim of this study was to evaluate the initial experience of NOSE surgery in minimally invasive surgery colorectal surgery in terms of feasibility and safety outcomes. Prospective data was collated for all cases of NOSE in colorectal surgery from Jan 2024 to Dec 2024. Data collected included patient demographics, comorbidities, underlying pathology, pre-, intra- and post-operative outcomes. There were 17 cases considered for NOSE surgery. Eight cases had successful transvaginal NOSE and six cases had successful transanal NOSE. The median age was 68.5 years (range 36-87 years). The median ASA was 3 (range 1-4). All the transvaginal NOSE were performed with laparoscopic right hemicolectomy for neoplasia. Of the six transanal NOSE, four were performed for benign and two for malignant indications. There were no intraoperative complications with no conversion to open surgery. There were no post-operative complications especially anastomotic leak, ileus, wound infection, and extraction-site related complications in transvaginal NOSE cases. There was one anastomotic leak in transanal NOSE that required laparoscopic washout and defunctioning ileostomy. All the neoplasia cases achieved satisfactory oncological outcomes (R0 resection & adequate lymph node yield). The median follow-up was 6 months (range 2-11). The early experience of NOSE in colorectal surgery is safe and feasible in well selected group of patients. It avoids abdominal wall trauma from extraction with reduction of wound infection, pain and long-term risk of incisional hernia.

Keywords: Colectomy, NOSE, MIS, morbidity, outcomes 31

INTRODUCTION

Minimally invasive surgery in colorectal surgery has evolved significantly in the last few decades. The laparoscopic techniques are established in most centres. Laparoscopic colorectal resections usually involve laparoscopic mobilization of the colon followed by a mini-laparotomy for exteriorization to complete the anastomosis. Despite the overall improvement over open surgery, this approach still carries some morbidities ranging from ileus, wound infections and long-term development of incisional hernias (1,2). There is recent interest to embark on intracorporeal anastomosis (ICA) to reduce the ileus rates (3) and this allows off-midline extraction which has a reduced wound infection and hernia rate (4).

Natural orifice specimen extraction surgery (NOSE) has been around for some time (5). It is seen as a bridge between conventional laparoscopic surgery and natural orifice endoscopic transluminal endoscopic surgery (NOTES) (6). NOTES is technically challenging (6) whereas in NOSE surgery, the whole surgery is performed as usual techniques apart from the extraction. NOSE can be performed through the anus (Ta), vagina (Tv) or transcolonic (Tc) in the setting of colorectal surgery (7). It has the advantage of avoiding any potential abdominal wall morbidities and reduces post-operative pain (8,9). This approach is only limited to a few centres and only a handful of Australian units have adopted this approach (10,11). Our unit has adopted ICA in colorectal resections routinely and started to offer NOSE in selective cases.

The aim of this study was to evaluate the initial experience with feasibility and safety of NOSE in laparoscopic colorectal surgery in our unit.

MATERIAL and METHODS

This was a review of the prospectively maintained database of all NOSE surgery performed from January 2024 to December 2024. Ethics approval (670/24) was obtained from the ethics committee. The patients' demographics, the comorbidities,

Cite this article as: Ng ZQ, Lokuhetty N, Macdonald C, Warriar S. The initial experience of natural orifice specimen extraction surgery in laparoscopic colorectal surgery. *Turk J Surg.* 2025;41(2):204-211

Corresponding Author

Zi Qin Ng

E-mail: kentng@hotmail.co.uk

ORCID ID: orcid.org/0000-0002-6272-4640

Received: 28.01.2025

Accepted: 17.04.2025

Epub: 13.05.2025

Publication Date: 30.05.2025

DOI: 10.47717/turkjsurg.2025.6738

Available at www.turkjsurg.com



previous abdominal surgery, colorectal pathology, the pre-, intra- and post-operative details, histopathology and follow-up were collated. The last clinic follow-up was considered the last follow-up in this study.

Patient Selection

The cases were carefully selected for their suitability. The inclusion criteria for transvaginal NOSE were female patients, consenting to transvaginal extraction, T0-T3 tumors, size of tumour <6 cm, no peritoneal disease and elective cases. The exclusion criteria were: T4/perforated tumours (Figure 1), metastatic disease, emergency cases, child-bearing age females, large multifocal fibroids (Figure 2) inhibiting easy access to the posterior vagina and previous pelvic radiation/gynaecological cancers.

The inclusion criteria for transanal NOSE were benign cases including diverticular disease, sigmoid volvulus and for malignant cases of resected malignant left colonic polyp. The details of the operation were explained in the clinic and informed consent was obtained from the patient. If NOSE was not feasible intraoperatively, a pfannenstiell incision was then performed.

Technique for Transvaginal NOSE

Our technique has previously been published (12). Briefly, the patient is placed in a lithotomy position with reverse

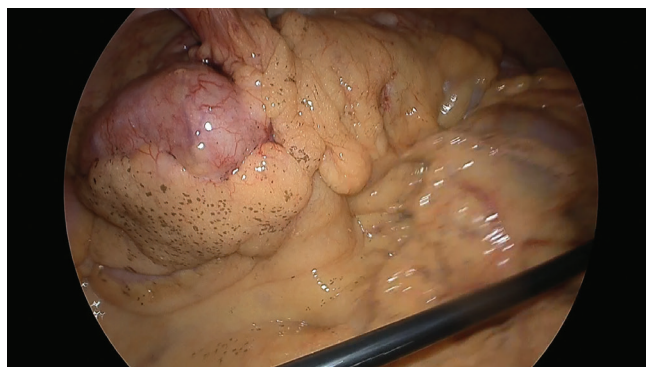

Figure 1. An example of intraoperative finding of large caecal tumour with potentially T4 disease.

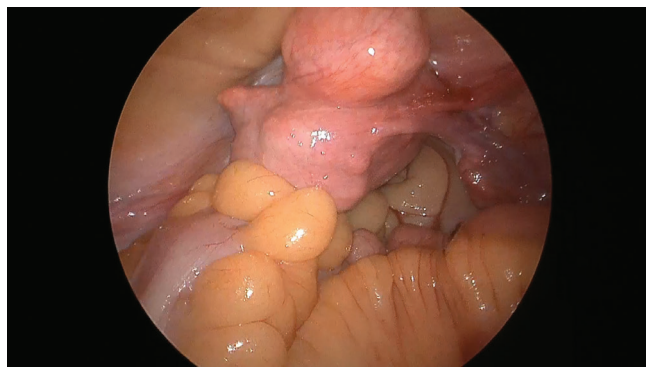


Figure 2. Large multifocal uterine fibroid precluding easy access for transvaginal natural orifice specimen extraction.

Trendelenburg and right tilt position. A beanbag is used to ensure the patient does not slip down on the table. Bilateral calf compressors are used.

Indwelling catheter is used. Standard prophylactic intravenous antibiotics (2 g cephazolin and 500 mg metronidazole) were given.

The vagina is examined for any strictures and irrigated with povidone-iodine solution prior at the start of the case.

A 5 mm optical entry at the Palmer's point is utilized. Further two 5 mm and one 12 mm ports are placed under vision. Bilateral transabdominis plane blocks are performed with 20 mLs of 0.75% ropivocaine diluted into 60 mLs. The right hemicolectomy is performed in the conventional approach. ICA is performed.

The pelvis is examined for any adhesions which are divided sharply. The uterus if present is hitched up transabdominally to allow easy access to the posterior vagina.

The assistant irrigates the vagina again with povidone-iodine solution. A rectal sizer is inserted to guide the posterior fornix of the vagina. Posterior colpotomy is performed with diathermy laparoscopically. A small Alexis wound retractor is placed through the vagina.

A Rampley's forceps is used to extract the specimen through the vagina. The wound retractor is removed, and a temporary pack is inserted into the vagina to allow re-establishment of pneumoperitoneum. The vagina is closed with 3/0 absorbable V-Loc suture. The vagina is examined to ensure there is no residual defect.

A vagina pack soaked in Povidone-iodine is placed in the vagina overnight.

Technique for Transanal NOSE

Our technique has previously been demonstrated (13). The positioning is similar to the aforementioned except for a left tilt position.

An on-table colonoscopy is performed to confirm the diagnosis and perform washout with povidone-iodine (14).

Three 5 mm and one 12 mm ports are used. The left colon is mobilized in the usual manner.

The splenic flexure is routinely mobilized in all cases. For malignant polyp cases, a high ligation of the inferior mesenteric artery is performed. For benign cases, a low ligation is performed with preservation of the superior rectal artery.

The upper rectum is stapled off with an endoscopic stapler. The proximal mesocolon is ligated with an energy device. The proximal colonic margin is determined and divided with an endoscopic staple. The rectal staple line is removed.

A small Alexis wound retractor is placed through the rectum. The anvil of the circular stapler is introduced through the anus into the peritoneal cavity. The assistant then uses a Rambley's forceps to extract the specimen. For bulky diverticular disease specimen, the mesentery is separated from the colon. In certain cases, the colon needs to be removed in piecemeal.

The wound retractor is removed. The rectal stump is closed with an endoscopic stapler. Indocyanine green is performed to assess for the perfusion of the colonic conduit and the rectum. A purse-string of the conduit is created intra-corporeally with 3/0 V-Loc. The anvil is inserted and further secured with a PDS endoloop. An end-to-end colorectal anastomosis is created with a circular stapler.

Alternatively, the anvil inserted into the colonic conduit following removal of the staple line and the spike is delivered through the antimesenteric border. The colostomy is closed off with an endoscopic stapler. A side-to-end colorectal anastomosis is created with a circular stapler.

A flexible sigmoidoscopy is performed to assess the colorectal anastomosis and pneumatic test. All the cases were performed by the fellow (ZN) who has had prior experience in laparoscopic NOSE surgery under the supervision of the consultant surgeon (SW).

Post-operative Care

Enhanced recovery after surgery (ERAS) principles were followed. Nasogastric tube or drains were not placed. Free fluids were given immediately post-operation. A full diet was allowed on day 1.

The vagina pack and the indwelling catheter were removed at 6.00 am on day 1. Patients were advised to have no sexual intercourse for 6 weeks post-operation. Patient was followed up in clinic in two weeks' time for clinical review (Figure 3).

The pain score was recorded based on the last documentation prior to discharge. The pain score was assessed by the nursing staff.

RESULTS

Demographics

During the study period, a total of 17 patients were considered for NOSE. Of the 17 patients, 10 were considered for NOSE-Tv and seven for NOSE-Ta. Eight patients underwent laparoscopic right hemicolectomy with NOSE-Tv (Table 1) and six underwent laparoscopic anterior resection with NOSE-Ta (Table 2). The median age was 68.5 years (range 36-87 years). All NOSE-Tv were female patients. For NOSE-Ta, there were four males and two females. The comorbidities were listed in the table. The median ASA was 3 (range 1-4). The median BMI was 27.5 (18.8-40.3) for NOSE-Tv and 28.4 (23.1-50) for NOSE-Ta respectively.

NOSE-Tv

The surgery was performed for neoplasia in all cases; four cancers, three malignant polyps and one advanced polyp. Conventional D2 laparoscopic right hemicolectomy was performed in four patients and complete mesocolic excision with central vascular ligation was performed in four patients. All the ICAs were performed in an isoperistaltic side-to-side stapled configuration.

Two cases required adhesiolysis in the pelvis from previous hysterectomy. A wound retractor was used in all cases. There was no conversion to open surgery. There were no intraoperative complications. The remaining two cases considered for NOSE-Tv were found to have larger tumour and hence a pfannenstiell incision was performed instead.

The median operative time was 188.5 min (range 137-247 min). One patient had planned intensive care unit (ICU) for observation overnight due to underlying comorbidities of liver cirrhosis. One patient had unplanned ICU admission due to asymptomatic hypotension from the spinal anaesthesia (for chronic pain). There were no anastomotic leaks. The median time to flatus and bowel movements were 1 day (range 0-3) and 1 day (range 1-3) respectively.

The median pain score prior to discharge was 0 (range 0-5). The median length of stay was 2.5 days (range 23 hours-8 days). One patient was clinically cleared for discharge on day three but waited for rehabilitation on day eight for underlying frailty and malnutrition.

On clinic follow-up, there were no wound-related complications. There were no extraction-site related complications on follow-up.

Histopathology results are detailed in Table 1. All the specimens had R0 and clear resection margins. The median lymph node

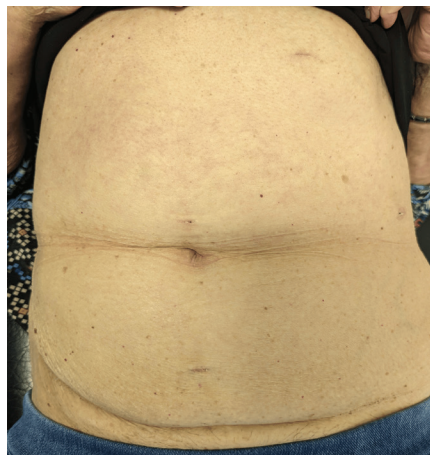

Figure 3. Clinic review of the patient's abdomen 2 weeks after laparoscopic right hemicolectomy with transvaginal NOSE.

NOSE: Natural orifice specimen extraction surgery

Table 1. The peri-operative details of patients that underwent NOSE-Tv

Case	Sex	Age (years)	Comorbidities	ASA	Previous abdominal surgery	BMI	Pathology	Surgery	Operative time (mins)	Day to flatus
1	Female	60	Necrotising myopathy on rituximab and prednisolone	2	Hysterectomy	24	Malignant ascending colon polyp (polypectomy)	RH	168	3
2	Female	79	Heart failure, COPD, AF, CKD 3	3	Nil	29.3	Malignant caecal polyp (EMR)	RH	207	2
3	Female	72	CKD 2	2	Open appendicectomy	26.7	Caecal cancer	RH	247	1
4	Female	71	Liver Cirrhosis Childs Pugh A from alcohol, Heart Failure, Malnutrition, Pulmonary embolism on therapeutic anticoagulation, legally blind	3	Nil	18.8	Hepatic flexure cancer	RH	190	2
5	Female	73	Chronic back pain	3	Hysterectomy	29.2	Malignant hepatic flexure polyp (EMR)	RH	137	1
6	Female	86	CKD 3, Fatty liver, AF, OSA, Type 2 diabetes	3	Hysterectomy	40.3	Caecal cancer	RH	230	0
7	Female	66	Marginal zone lymphoma	3	Caesarean section	22.5	Hepatic flexure cancer	RH	187	1
8	Female	87	CKD 3, AF, previous rectosigmoid cancer	4	High anterior resection	29	Large recurring caecal polyp	RH	160	1

Day to bowel movement	Pain score on discharge	Length of stay (day)	Size of tumour (mm)	Histopathology	Lymph node	R0/ Margins	Comments
3	2	3	-	Nil residual cancer	0/24	Clear	-
2	0	4	Incidental neuroendocrine tumour 11x10	Nil residual adenocarcinoma. Incidental terminal neuroendocrine tumour	4/25 (neuroendocrine)	Clear	-
1	0	23 hours	50x33	T2/N0	0/18	Clear	-
2	0	8	27x20	T3/N0	0/17	Clear	Clinically ready for discharge day 3, awaited rehabilitation for malnutrition
1	0	3	-	No residual cancer	0/32	Clear	Rural patient
0	1	2	25x16	T2/N0	0/16	Clear	-
1	5	2	40x26	T3/N0	0/24	Clear	No pick up available on day 1
1	1	2	16x12	Tubular adenoma with high grade dysplasia	0/15	Clear	Rural patient

COPD: Chronic obstructive pulmonary disease, CKD: Chronic kidney disease, AF: Atrial fibrillation, OSA: Obstructive sleep apnea, EMR: Endoscopic mucosal resection, RH: Right hemicolectomy, NOSE: Natural orifice specimen extraction surgery

Table 2. The peri-operative details of patients that underwent NOSE-Ta

Case	Sex	Age (years)	Comorbidities	ASA	Previous abdominal surgery	BMI	Pathology	Operative time (min)	Day to flatus	Day to bowel movement	Pain score on discharge	Histopathology	Lymph node	R0/ Margins
1	M	37	Ex-smoker	2	Lap Morgagni hernia repair	30.4	Recurrent sigmoid diverticulitis	232	1	1	2	Complicated diverticulitis	-	-
2	M	86	Ex-smoker	3	Nil	26	Recurrent sigmoid volvulus	140	1	2	0	Sigmoid volvulus	-	-
3	M	54	Asthma	2	Laparoscopic lavage	26.3	Recurrent sigmoid diverticulitis	288	2	2	2	Complicated diverticulitis	-	-
4	F	57	Nil	1	Open right nephrectomy	33.6	Malignant sigmoid polyp	178	1	1	1	Nil residual cancer	0/23	Clear
5	F	36	Morbid obesity	3	Nil	50	Malignant sigmoid polyp	175	1	1	2	T3/N2	7/28	Clear
6	M	40	Smoker	3	Nil	23.1	Recurrent sigmoid diverticulitis	227	1	2	2	Complicated diverticulitis	-	-

BMI: Body mass index, NOSE: Natural orifice specimen extraction surgery

yield was 21 (range 15-32). In the median follow-up of 6 months, there was no local or distant recurrence.

NOSE-Ta

The surgery was performed for recurrent sigmoid diverticulitis in three patients, recurrent sigmoid volvulus in one patient and malignant polyp in two patients. Five patients had end-to-end and one had side-to-end colorectal anastomosis. A wound retractor was used in all cases. There was no conversion to open surgery. There was no intraoperative complication. Of the seven cases considered for NOSE-Ta, one required conversion to a lower midline laparotomy for frozen pelvis from chronic sigmoid diverticulitis.

The median operative time was 202.5 min (range 140-288 min).

There was a case of small anastomotic leak on day three that required a return to theatre for laparoscopic washout and defunctioning loop ileostomy. The patient since had a healed colorectal anastomosis and reversal of loop ileostomy five months later. The median time to flatus and bowel movement were 1 day (range 1-2) and 1.5 days (range 1-2) respectively.

The median pain score prior to discharge was 2 (range 0-2). The median length of stay was 4 days (range 1-17). On clinic follow-up, there were no wound-related complications.

There were no extraction-site related complications on follow-up. Histopathology results are detailed in Table 2.

DISCUSSION

This study has demonstrated the initial experience of laparoscopic colorectal surgery with both transvaginal and transanal NOSE procedures.

The application of NOSE is significantly easier as compared to NOTES which has unfamiliar views and clash of instruments. NOSE retains all the familiarity of the established laparoscopic colorectal techniques with 5-12 mm port placements (6). The published literature in Australia is mainly limited to a single centre publication with large experience in both Tv- and Ta-NOSE surgery (10,14).

Earlier small series suggest that NOSE-TV is safe in laparoscopic right hemicolectomy (15-17). An earlier systematic review of 90 cases of NOSE-Tv found two cases of colonic/rectal injury sustained during NOSE-Tv (18). This could be avoided with careful selection of cases and meticulous extraction techniques as shown in our experience. An updated 2023 international guidelines on NOSE published the indications for different NOSE techniques (7).

The safety of NOSE in malignant cases often raises concerns. It is important to emphasize that the oncological resection principles are not compromised (19). We showed that all the malignant cases achieved R0 resection and adequate lymph

node yield. The potential for seeding in the vagina or rectum/anus during extraction is akin to the initial reports of port sites malignant recurrence during the initial adoption of laparoscopic surgery (20). The key aspects to protect against this are the use of a wound protector for extraction, gentle traction of the specimen and irrigation with povidone-iodine.

For NOSE-Ta cases, we strictly select only cases of resected malignant polyps and benign indications although it can be done for left colonic malignancy (9,21). We do not recommend debulking the mesentery or colon for malignant indications. For NOSE-Tv cases, we assess intraoperatively. In cases where there is doubt about the size of the tumour, a ruler can be used to measure intraoperatively (Figure 4). A study found that mean tumour size 6.5 cm +/- 4.2 cm failed in NOSE (22). Different tumour sizes have been published as cut-off for NOSE-Tv. Our experience has been similar to Seow-En et al. (23) where the width of the pelvic outlet and vaginal conduit need to be considered as well. In scenarios where there are significant pelvic adhesions requiring prolonged adhesiolysis or large subserosal fibroids precluding easy access to the posterior vagina, NOSE can be abandoned. Pre-operative evaluation of the endoscopic images of the primary tumour and CT images of the primary tumour and uterus (Figure 5) are important for operative planning. Larger series of NOSE-Tv have not found any local recurrence cases (22). Local recurrence in the vagina has been limited to a case report.

Another concern for following NOSE-Tv is on the sexual function. The studies have shown that there was no impact on the long-term sexual function following NOSE-Tv (8,23-25).

We have not offered NOSE-Tv to child-bearing age females in keeping with most centres' exclusion criteria (15-17). For NOSE-Ta, studies have shown there is no impairment of the anorectal function (19,21). We have not observed that but will require a long-term survey to assess that.

There are a few technical details to discuss. To perform NOSE, the clinician should be proficient in ICA techniques. In Tv-NOSE

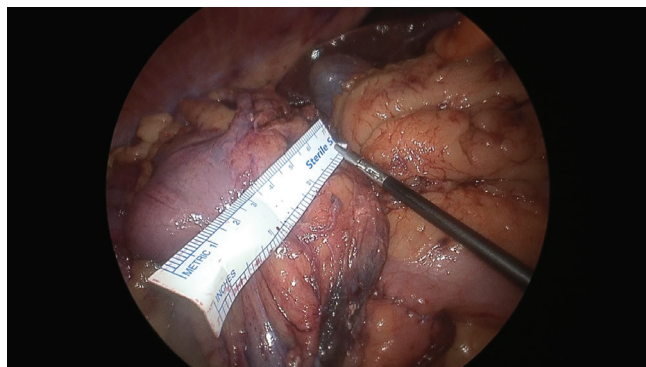


Figure 4. Intraoperative measurement of the tumour size with a ruler and abandoning transvaginal NOSE.

NOSE: Natural orifice specimen extraction surgery

for laparoscopic right hemicolectomy, the ICA is performed as usual technique as it is not linked to the extraction aspect of the procedure.

There was a case of small anastomotic leak early on in NOSE-Ta which could be related to technical factor while creating the purse-string. It is vital to have full thickness decent bites of the bowel during purse-string. The anvil should also be secure and snugged. We do not think it was secondary to a rectal injury from the NOSE-Ta extraction. An alternative way is to perform a Baker-type anastomosis (side-to-end) which precludes the need for intracorporeal purse-string. For NOSE-Tv, using a larger needle such as 2/0 is easier to close the posterior colpotomy. Alternatively, this can be performed extra-corporeally.

The average length of stay following colonic surgery remains around 3-4 days despite the routine practice of ERAS (26). The next challenge is to bridge the gap between ERAS and ambulatory colectomy (27). The two factors that often concern patients and/or clinicians from discharge are ability to tolerate diet and post-operative pain (28). We did not have a comparison group to demonstrate the reduction in post-operative ileus rates but can be reflected in the median time to return of bowel movement and flatus (median one day). With NOSE, the patients had low median post-operative pain and need of opioids on discharge. The benefits extend even further to obese (10) and comorbid patients.

This study is limited by the small numbers as a report of initial experience. The operative time may not be fully reflective

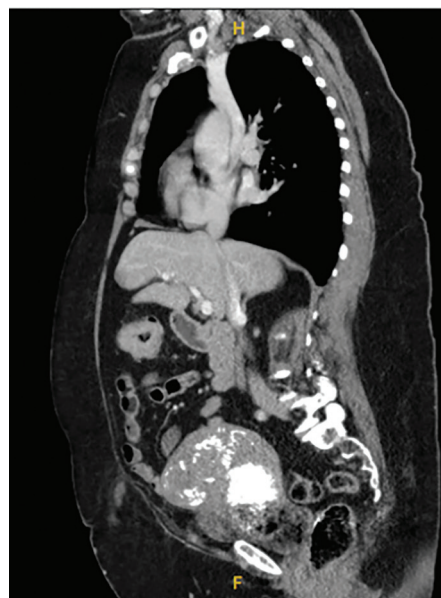

Figure 5. Preoperative sagittal view of CT scan for assessment of the uterus where the large fibroid made transvaginal NOSE not suitable.

NOSE: Natural orifice specimen extraction surgery, CT: Computed tomography

as the author was initially on the learning curve of ICA followed by complete mesocolic excision in laparoscopic right hemicolectomy. In some of the cases of NOSE-Ta, the operative time included the time for cystoscopy and bilateral ureteric catheters insertion for the diverticular disease cases. Nevertheless, the operative time is comparable to larger series (8,10,14). A learning curve analysis for NOSE surgery was not possible due to the small numbers but with appropriate mentoring, this study has demonstrated its feasibility even in the hands of a fellow.

CONCLUSION

The introduction of NOSE in laparoscopic colorectal surgery is safe and feasible in our early experience. NOSE surgery in a well-selected group of patients offers additional benefits of reduced post-operative pain, and post-operative complications related to abdominal wall extraction of specimen. The techniques of NOSE surgery will continue to evolve and mature.

Ethics

Informed Consent: Informed consent was obtained from the patients.

Footnotes

Author Contributions

Concept - Z.Q.N., S.W.; Design - Z.Q.N., S.W.; Fundings- Z.Q.N., N.L., C.M.; Materials - Z.Q.N., N.L., C.M., S.W.; Data Collection or Processing - Z.Q.N., C.M.; Analysis or Interpretation - Z.Q.N., N.L., C.M., S.W.; Literature Search - Z.Q.N., N.L., C.M.; Writing - Z.Q.N., N.L., C.M.

Conflict of Interest: No conflict of interest was declared by the authors.

Financial Disclosure: The authors declared that this study received no financial support.

REFERENCES

- Selznick S, Levy J, Bogdan RM, Hawel J, Elnahas A, Alkhamesi NA, et al. Laparoscopic right colectomies with intracorporeal compared to extracorporeal anastomotic techniques are associated with reduced post-operative incisional hernias. *Surg Endosc.* 2023;37:5500-5508.
- Zattoni D, Popeskou GS, Christoforidis D. Left colon resection with transrectal specimen extraction: current status. *Tech Coloproctol.* 2018;22:411-423.
- Zhang T, Sun Y, Mao W. Meta-analysis of randomized controlled trials comparing intracorporeal versus extracorporeal anastomosis in minimally invasive right hemicolectomy: upgrading the level of evidence. *Int J Colorectal Dis.* 2023;38:147.
- Emile SH, Elfeki H, Shalaby M, Sakr A, Bassuni M, Christensen P, et al. Intracorporeal versus extracorporeal anastomosis in minimally invasive right colectomy: an updated systematic review and meta-analysis. *Tech Coloproctol.* 2019;23:1023-1035.
- Wolthuis AM, de Buck van Overstraeten A, D'Hoore A. Laparoscopic natural orifice specimen extraction-colectomy: a systematic review. *World J Gastroenterol.* 2014;20:12981-12992.
- Leung AL, Cheung HY, Li MK. Advances in laparoscopic colorectal surgery: a review on NOTES and transanal extraction of specimen. *Asian J Endosc Surg.* 2014;7:11-16.
- Liu Z, Guan X, Zhang M, Hu X, Yang M, Bai J, et al. International guideline on natural orifice specimen extraction surgery (NOSES) for colorectal cancer (2023 version). *Holistic Integrative Oncology.* 2023;2:9.
- Chang JHE, Xu H, Zhao Y, Wee IJY, Ang JX, Tan EK, et al. Transvaginal versus transabdominal specimen extraction in minimally invasive surgery: a systematic review and meta-analysis. *Langenbecks Arch Surg.* 2024;409:172.
- He J, Yao HB, Wang CJ, Yang QY, Qiu JM, Chen JM, et al. Meta-analysis of laparoscopic anterior resection with natural orifice specimen extraction (NOSE-LAR) versus abdominal incision specimen extraction (AISE-LAR) for sigmoid or rectal tumors. *World J Surg Oncol.* 2020;18:215.
- Lendzion RJ, Gilmore AJ. Laparoscopic right hemicolectomy with intracorporeal anastomosis and natural orifice surgery extraction/minimal extraction site surgery in the obese. *ANZ J Surg.* 2021;91:1180-1184.
- Pham TD, Larach T, Othman B, Rajkomar A, Heriot AG, Warriar SK, et al. Robotic natural orifice specimen extraction surgery (NOSES) for anterior resection. *Ann Coloproctol.* 2023;39:526-530.
- Ng ZQ, Warriar S. How to do laparoscopic right hemicolectomy with transvaginal natural orifice specimen extraction. *ANZ J Surg.* 2024;94:1167-1169.
- Ng ZQ, Warriar S. Laparoscopic anterior resection with transanal natural orifice extraction surgery and ureteric indocyanine green guidance - A video vignette. *Colorectal Dis.* 2024;26:2125-2126.
- Chen MZ, Cartmill J, Gilmore A. Natural orifice specimen extraction for colorectal surgery: Early adoption in a Western population. *Colorectal Dis.* 2021;23:937-943.
- Awad ZT, Qureshi I, Seibel B, Sharma S, Dobbertien MA. Laparoscopic right hemicolectomy with transvaginal colon extraction using a laparoscopic posterior colpotomy: a 2-year series from a single institution. *Surg Laparosc Endosc Percutan Tech.* 2011;21:403-408.
- Park JS, Choi GS, Lim KH, Jang YS, Kim HJ, Park SY, et al. Clinical outcome of laparoscopic right hemicolectomy with transvaginal resection, anastomosis, and retrieval of specimen. *Dis Colon Rectum.* 2010;53:1473-1479.
- McKenzie S, Baek JH, Wakabayashi M, Garcia-Aguilar J, Pigazzi A. Totally laparoscopic right colectomy with transvaginal specimen extraction: the authors' initial institutional experience. *Surg Endosc.* 2010;24:2048-2052.
- Kayaalp C, Yagci MA. Laparoscopic right colon resection with transvaginal extraction: a systematic review of 90 cases. *Surg Laparosc Endosc Percutan Tech.* 2015;25:384-391.
- Wang S, Tang J, Sun W, Yao H, Li Z. The natural orifice specimen extraction surgery compared with conventional laparoscopy for colorectal cancer: A meta-analysis of efficacy and long-term oncological outcomes. *Int J Surg.* 2022;97:106196.
- Emoto S, Ishigami H, Yamaguchi H, Ishihara S, Sunami E, Kitayama J, et al. Port-site metastasis after laparoscopic surgery for gastrointestinal cancer. *Surg Today.* 2017;47:280-283.
- Huang CC, Chen YC, Huang CJ, Hsieh JS. Totally laparoscopic colectomy with intracorporeal side-to-end colorectal anastomosis and transrectal specimen extraction for sigmoid and rectal cancers. *Ann Surg Oncol.* 2016;23:1164-1168.
- Karagul S, Kayaalp C, Sumer F, Ertugrul I, Kirmizi S, Tardu A, et al. Success rate of natural orifice specimen extraction after laparoscopic colorectal resections. *Tech Coloproctol.* 2017;21:295-300.
- Seow-En I, Khor SN, Koo CH, Wee IJY, Tan EK. Transvaginal natural orifice specimen extraction (NOSE) in laparoscopic colorectal cancer surgery with new insights on technique and patient selection. *Surg Laparosc Endosc Percutan Tech.* 2023;33:571-575.
- Zhang M, Hu X, Guan X, Zheng W, Liu Z, Jiang Z, et al. Surgical outcomes and sexual function after laparoscopic colon cancer surgery with

- transvaginal versus conventional specimen extraction: A retrospective propensity score matched cohort study. *Int J Surg.* 2022;104:106787.
25. Zheng W, Zhang M, Hu X, Tan W, Liu S, Ren J, et al. Influence of transvaginal laparoscopic surgery on sexual function, life quality and short-term efficacy of patients diagnosed with colorectal cancer. *Am J Transl Res.* 2022;14:5098-5106.
26. Clarke EM, Rahme J, Larach T, Rajkomar A, Jain A, Hiscock R, et al. Robotic versus laparoscopic right hemicolectomy: a retrospective cohort study of the Binational Colorectal Cancer Database. *J Robot Surg.* 2022;16:927-933.
27. Ng ZQ, Rajkomar A, Pham T, Warriar SK. Ambulatory colectomy in 2024 - is it time for consideration in Australia? *ANZ J Surg.* 2024;94:1676-1677.
28. Alshargawi N, Alhashemi M, Kaneva P, Baldini G, Fiore JF Jr, Feldman LS, et al. Validity of the I-FEED score for postoperative gastrointestinal function in patients undergoing colorectal surgery. *Surg Endosc.* 2020;34:2219-2226.