



Short term outcome of laparoscopic ventral mesh rectopexy for rectal and complex pelvic organ prolapse: case series

Fatma Ayça Gültekin¹

¹ Department of General Surgery, Zonguldak Bulent Ecevit University School of Medicine, Zonguldak, Turkey

ABSTRACT

Objective: Laparoscopic ventral mesh rectopexy (LVMR) is a technique gaining more recognition for the management of pelvic floor disorders, such as external rectal prolapse (ERP), high grade internal rectal prolapse (IRP) and rectocele. LVMR also allows correction of coexisted pelvic organ prolapse. This study aimed to evaluate the safety, efficacy and functional outcome of LVMR for rectal and complex pelvic organ prolapse.

Material and Methods: All patients who underwent LVMR from February 2014 to October 2017 were included into the study. The patients were evaluated preoperatively and three months postoperatively. Surgical complications and functional results in terms of fecal incontinence (measured with the Wexner Incontinence Score= WIS) and constipation (measured with the Wexner Constipation Score= WCS) were analyzed.

Results: Thirty (4 males) patients underwent LVMR. Seventeen (56.6%) patients had complex pelvic organ prolapse according to MRI findings. Median operative time and postoperative stay were 110 minutes and 4 days, respectively. No mesh-related complication and recurrence were observed. Before surgery, 21 (70%) patients had complained about symptoms of obstructed defecation. WCS decreased significantly from median 19 to 6 ($p < 0.001$). Pre-operative median WIS of 9 patients was 14 and went down to 6 postoperatively ($p = 0.008$). WCS significantly improved after LVMR in patients with symptomatic rectocele combined with enterocele or sigmoidocele ($p = 0.005$), and significant improvement was also observed in patients with symptomatic rectocele combined with gynecologic organ prolapse, preoperative median WCS was 18 and the postoperative value fell to 8 ($p = 0.005$).

Conclusion: LVMR is an effective surgical option for rectal and complex pelvic organ prolapse with short-term follow-up.

Keywords: Rectal prolapse, pelvic organ prolapse, laparoscopic ventral rectopexy

INTRODUCTION

Since laparoscopic ventral mesh rectopexy (LVMR) was reported by D'Hoore in 2004, it has become the most common surgical procedure for external rectal prolapse (ERP) in Europe (1). Currently, LVMR is not only performed for ERP but also increasingly performed for internal rectal prolapse (IRP) and obstructive defecation syndrome (ODS) (2-7). During LVMR, the rectum is mobilized ventrally and the rectovaginal septum is dissected to the lowest part of the pelvic floor. The anterior wall of the rectum is fixed to the sacral promontory with mesh. Ventral position of the mesh also helps to perform colpopexy. Suturing of the posterior vaginal fornix (or posterior vaginal vault) to the same mesh provides some degree of correction, and any associated vaginal vault prolapse and obliteration of the Douglas pouch prevent enterocele, too (8). Main advantages of the technique are nerve sparing limited anterior dissection of the rectum and reinforcement of the rectovaginal septum with mesh, which gives support to both posterior and middle pelvic compartment. Long term results of LVMR have shown that LVMR is safe and effective for the treatment of ERP, IRP and rectocele with low recurrence rate, good functional results and rare mesh related complications (3). Although LVMR is being progressively performed in Europe and United States of America, few studies come from non-western countries (9-11). This study aimed to evaluate our surgical and functional short-term results of LVMR in a small consecutive series of patients from Turkey. To the best of our knowledge, this series seems to be the first and largest case series of patients that underwent LVMR in Turkey.

Cite this article as: Gültekin FA. Short term outcome of laparoscopic ventral mesh rectopexy for rectal and complex pelvic organ prolapse: case series. Turk J Surg 2019; 35 (2): 91-97

Corresponding Author

Fatma Ayça Gültekin

E-mail: faycagultekin@yahoo.com

Received: 22.03.2018

Accepted: 24.04.2018

Available Online Date: 13.06.2019

© Copyright 2019 by Turkish Surgical Society Available online at www.turkjsurg.com

DOI: 10.5578/turkjsurg.4157

MATERIAL and METHODS

Study Design

This observational cohort study is a retrospective analysis conducted in a tertiary referral center in Turkey. Between February 2014 and October 2017, LVMR was performed in 30 consecutive patients with ERP, IRP or symptomatic rectocele by one EBSQ-Coloproctology (European Board of Surgical Qualification in Coloproctology) certified colorectal surgeon. The study received ethical approval from the Hospital Ethics Committee. Informed consent was obtained from all of the patients.

Patients and Evaluation

Indications for LVMR were ERP, high grade IRP and/or rectocele associated with fecal incontinence or obstructed defecation. In addition, vaginal vault prolapse or uterovaginal prolapse could be present. All rectocele patients had failed in at least 3 months maximal conservative treatment (dietary modifications, laxatives and biofeedback therapy). Preoperative work-up comprised a complete history and physical examination and a flexible sigmoidoscopy/colonoscopy. Patients with ERP did not undergo any further investigations. A dynamic MR-defecography was performed to confirm diagnosis of IRP, rectocele and/or enterocele. Descending perineum (DP) > 3 cm was also a recorded pelvic structural abnormality during dynamic MR-defecography. IRP was classified into high grade and low grade using the Oxford rectal prolapse grading system (12).

Patient characteristics, previous surgery, perioperative data, length of hospital stay and complications (30 day postoperative complications) were obtained from the electronic medical database.

Functional outcomes were assessed preoperatively and three months after LVMR by Wexner incontinence score (WIC) and Wexner constipation score (WCS) (13,14).

Surgical Technique

The surgical technique for LVMR was adopted from the technique described by D'Hoore et al, with a few modifications as previously reported (1,15,16). In brief, the patients were placed in steep Lloyd-Davies position using special stirrups (Yellofin; Allen Medical, Massachusetts, USA). A 30-degree scope was placed in the sub-umbilical position with Hasson Technique, followed by the placement of 12-mm working port in the right iliac fossa and 5-mm ports each in the left lower quadrant and the right lateral abdominal wall. A very superficial peritoneal incision was created on the right side of the sacral promontory and continued on the right pararectal plane down to deepest part of the pouch of Douglas with a small extension onto the left side. The rectovaginal septum was dissected down to the level of the pelvic floor muscles. The lateral stalks were kept intact (Figure 1). L-shaped polypropylene mesh (Figure 2) was fixed to the pelvic-floor musculature on both sides of the rectum with absorbable tacks (Figure 3). The mesh was laid along the right side of the rectum with

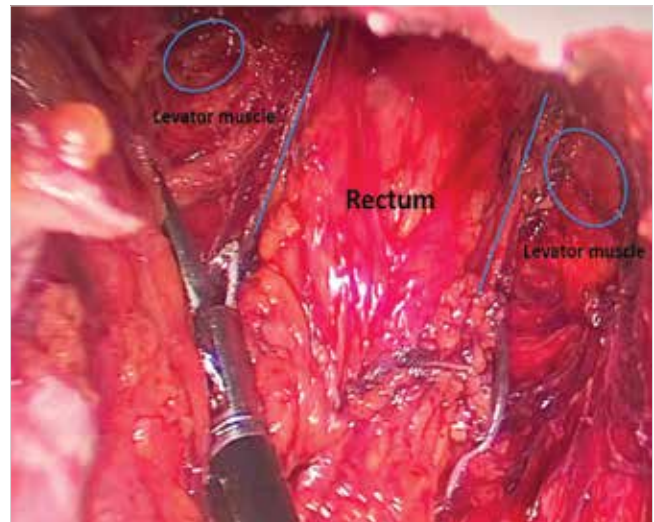


Figure 1. Dissection of the recto-vaginal septum and pelvic-musculature.

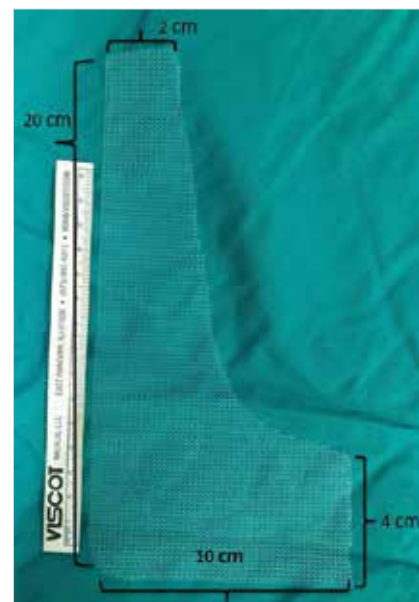

Figure 2. Preparation of the polypropylene mesh, which was trimmed to an L-shaped configuration.

the proximal end fixed to the sacral promontory with nonabsorbable tacks (Figure 4). If middle compartment prolapse was present, vaginal fornix (or posterior vaginal vault) was suspended and sutured to the same mesh. The peritoneum was then closed over the mesh with 2/0 absorbable vicryl suture.

Statistical Analysis

Statistical analyses were performed with SPSS 19.0 software (SPSS Inc., Chicago, IL, USA). Variables were expressed as mean \pm std. deviation and categorical variables as frequency and percent. Continuous variables were compared with Mann-Whitney

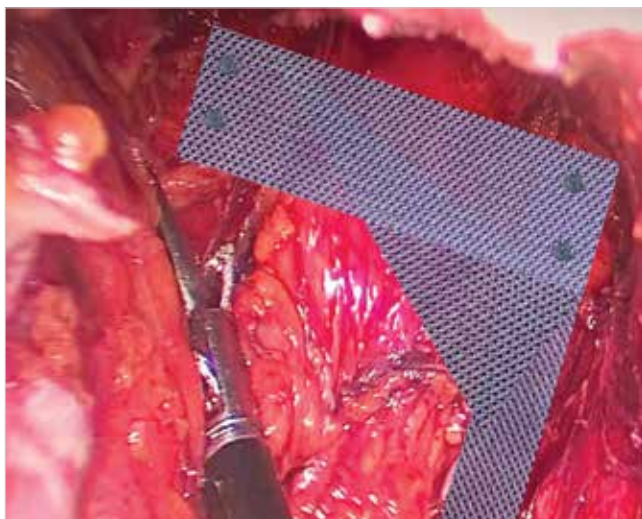


Figure 3. The polypropylene mesh was secured onto the pelvic-floor musculature on either side of the rectum with absorbable tacks.

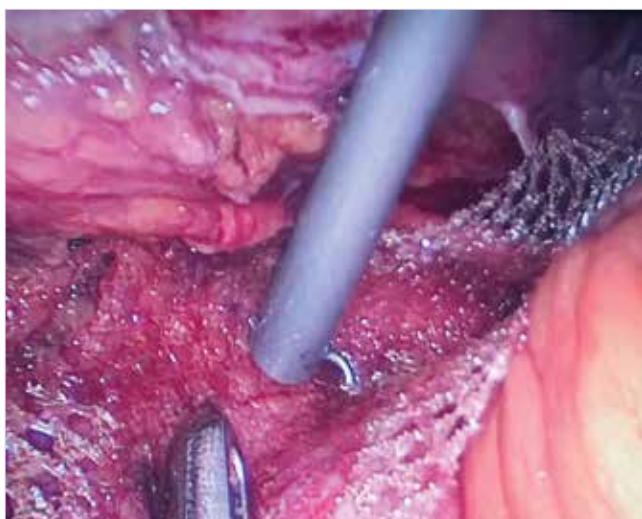


Figure 4. Proximal end of the polypropylene mesh fixed to the sacral promontory with nonabsorbable tacks.

U test. Repeated measures were evaluated with Wilcoxon Signed Rank test. P value of less than 0.05 was considered statistically significant for all tests.

RESULTS

A total of 30 patients (26 females) had LVMR between February 2014 and December 2017. Median follow-up time after LVMR was 23.9 months (range: 4-42.1). Patient characteristics and operative data are listed in Table 1. Mean age was 54.3 (\pm 13.6) (median = 53; range: 19-82) and mean BMI was 29.8 kg/m² (\pm 5.9). A history of previous abdominal or pelvic surgery was assessed in 30% of the patients. Patients were classified as ASA I (10%), ASA II (53%), ASA III (27%) and ASA IV (10%). At physical examination, nine patients had an ERP and 20 a recto-

Table 1. Patient characteristics and operative data

Variable	Value
Female/male	26/4
Age (years) (mean \pm SD)	54.3 (\pm 13.6)
BMI (kg/m ²) (mean \pm SD)	29.8 (\pm 5.9)
Previous abdominal surgery, n (%)	9 (30%)
Physical examination	
Rectal prolapse	9
Rectocele	16
Rectocele + vaginal vault prolapse	1
Rectocele + uterovaginal prolapse	1
Rectocele + perineal descensus	2
Normal	1
ASA* Score, n (%)	
ASA I	3 (10%)
ASA II	16 (53%)
ASA III	8 (27%)
ASA IV	3 (10%)
Operation time, (minute) (median, range)	110 (80-300)
Length of hospital stay, days (median, range)	4 (3-8)
Postoperative 30 day complications, n (%)	-
Follow-up (months) (median, range)	23.9 (4-42.1)

* ASA: American society of anaesthesiologists.

cele. Three patients had a concurrent descending perineum, vaginal vault and uterovaginal prolapse. Preoperative imaging results are summarized in Table 2. Dynamic MR-defecography was performed in 21 patients. Enterocoele and sigmoidocoele were identified on dynamic MR-defecography in 7 patients. In six patients, descending perineum in combination with rectocele was found on dynamic MR-defecography. In a patient with symptoms of ODS and normal physical examination, dynamic MR-defecography showed grade III IRP. On imaging studies, 56.6% (17/30) patients showed at least two different forms of co-existing abnormalities.

Surgery was performed laparoscopically in all patients. Median total operating time was 110 minutes (range: 80-300 minutes). Extensive endometriosis resulted in a perforation of the vagina in one patient. The defect was closed laparoscopically with sutures, and the procedure was completed with placement of the mesh. No postoperative early (< 30 days) complication was observed. Median hospital stay was 4 days (range: 3- 8 days). Preoperatively, nine patients reported fecal incontinence. WIS preoperatively varied from 10 to 20 (median: 14) and went down to 6 (range: 4-8), postoperatively. The difference was statistically significant ($p= 0.008$) (Figure 5). Twenty-one patients had symptoms of ODS with median WCS 19 (range: 14-26) and

Table 2. Dynamic magnetic resonance (MR)-defecography findings patients with rectocele

Physical examination	Dynamic MR*-defecography findings	n
Rectocele	Rectocele	3
Rectocele	Rectocele + enterocele	5
Rectocele	Rectocele + sigmoidocele	2
Rectocele	Rectocele + perineal descensus	6
Rectocele + vaginal vault prolapse	Rectocele + vaginal vault prolapse	1
Rectocele + uterovaginal prolapse	Rectocele + uterovaginal prolapse	1
Rectocele + perineal descensus	Rectocele + perineal descensus	2

* MR: Magnetic resonance.

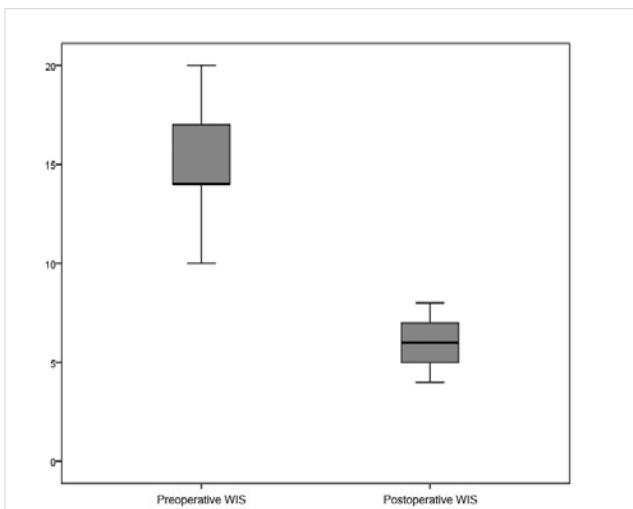


Figure 5. Preoperative and postoperative Wexner Incontinence Score (WIS) for patients with external rectal prolapse.

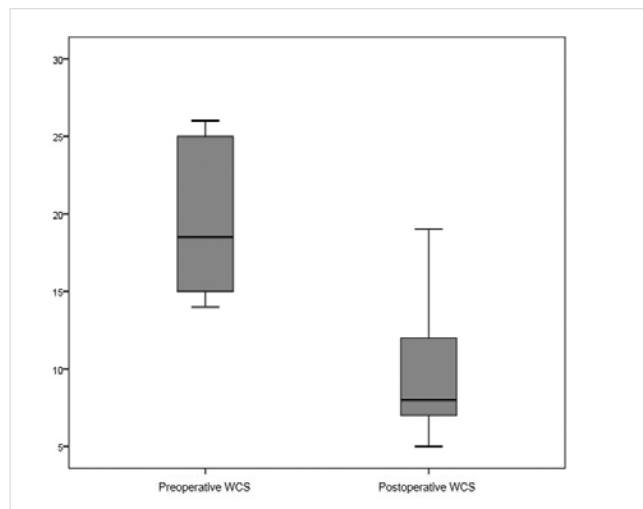


Figure 7. Preoperative and postoperative Wexner Constipation Score (WCS) for patients with symptomatic rectocele combined with gynecologic organ prolapse (descending perineum, vaginal vault and uterovaginal prolapse).

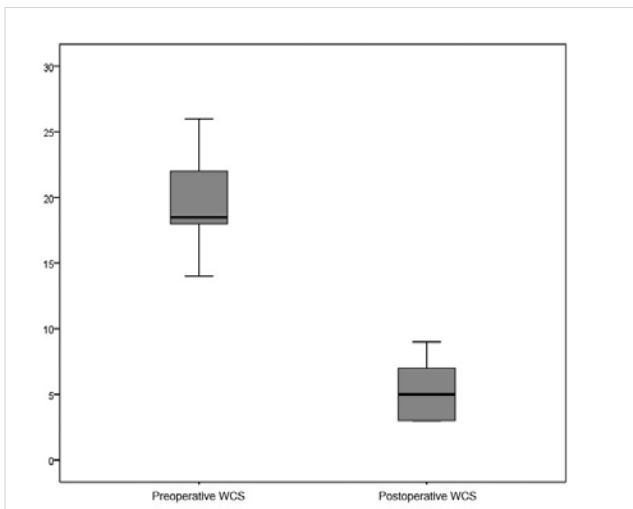


Figure 6. Preoperative and postoperative Wexner Constipation Score (WCS) for patients with symptomatic rectocele combined with enterocele or sigmoidocele.

the postoperative value fell to 6 (range: 3-19). The difference was statistically significant ($p < 0.000$). Functional outcome evaluated separately in patients with symptomatic rectocele combined with enterocele or sigmoidocele and gynecologic organ prolapse (descending perineum, vaginal vault and uterovaginal prolapse). WCS significantly improved after LVMR in both patient groups. WCS before surgery was 10 (median, range 14-26), decreasing to 5 (range 3-9) postoperatively in patients with symptomatic rectocele combined with enterocele or sigmoidocele; this difference was statistically significant ($p = 0.005$) (Figure 6). Statistically significant improvement in WCS was noted in patients with symptomatic rectocele combined with gynecologic organ prolapse (descending perineum, vaginal vault and uterovaginal prolapse), the preoperative score was 18 (median, range: 14-26) and the postoperative value fell to 8 (median, range: 5-19) ($p = 0.005$) (Figure 7). In a patient with grade III IRP, WCS decreased from 22 to 7.

DISCUSSION

This study reports the outcome of 30 patients undergoing LVMR for ERP, IRP and symptomatic rectocele. To the best of our knowledge, our 30-case series of LVMR represents the largest case series from Turkey to date. Among Turkish surgeons transanal techniques (Altemeire or Delorme procedure) are used for frail patients with ERP, but for surgically fit patients, Frykman-Goldberg procedure (Resection rectopexy) or suture rectopexy are preferred for the treatment of ERP. Various transanal (Stapled transanal rectum resection (STARR)) and transperineal (Transperineal mesh repair) techniques are adopted for the treatment of IRP and symptomatic rectocele according to surgeon experience in Turkey.

LMVR is currently adopted by many colorectal surgeons from Europe and North America as the established procedure for the treatment of ERP, IRP and symptomatic rectocele (1,3-7,17). Despite supporting data about the advantages and long-term outcome of LVMR worldwide, this procedure has gained very low acceptance among Turkish surgeons. First advantage of LVMR is preserving rectal ampulla, which is very important for restoring the continence. Secondly, as the ventral position of the mesh reinforces vaginal septum and prevents descent of the pelvic floor, LVMR corrects both posterior and middle compartments prolapse. Moreover, limited anterior dissection and avoiding division of the lateral rectal stalk prevent postoperative new-onset constipation or worsening pre-existing constipation (1,8). Long-term outcome of LVMR has shown that LVMR is a safe and effective procedure with good patient satisfaction and low rates of recurrence. The rates of complications and mesh-related problems are limited, and the number of de-novo symptoms is acceptable (3,16,18).

This series is primarily a learning experience, documenting the introduction of LVMR into a tertiary health care center of Turkey. Although follow-up is short, it does demonstrate the feasibility of performing LVMR. The procedure can be introduced successfully without requiring excessive operating time, length of hospital stay or resulting in increased morbidity. No mesh related complication was observed in our series. However, the data in the US Food and Drug Administration report emphasizes that mesh erosions tend to occur within 12 months after surgery, therefore in the current study, long-term follow-up was necessary for identified mesh related complications (19). Previous multicenter studies have reported 1.3% to 2.0% mesh erosion rates (3,18). Type of mesh is another important consideration about mesh related complication of LVMR. In our series, we preferred to use polypropylene mesh. In an international collaboration of surgeons reporting 2203 ventral rectopexy patients, it has been stated that synthetic mesh was used in 1764 (80.1%) and biological graft in 439 (19.9%). A total of 45 (2%) patients had mesh erosions, and at time of analysis, 2.4% (42/1764) and 0.7% (3/439) mesh erosion rates were identified in patients with

synthetic mesh and biological graft, respectively (18). However, when recurrence rate is considered, there is no circumstantial evidence to support the use of one type of mesh over the other (20). In our series, no recurrence was observed since follow-up was short, and for evaluation of real recurrence rate after LVMR, a longer follow-up time of at least 5 years is necessary. However, we believe that in order to prevent early technical failure, a firm fixation of the mesh to the sacral promontory and rectum/pelvic-floor musculature has a vital importance.

A recent consensus report, by a panel of international experts, considers ERP as a definitive indication for ventral mesh rectopexy (2). In an observational study of long-term outcome of 919 consecutive patients after ventral mesh rectopexy, 242 ERP patients showed a decrease of fecal incontinence complaints from 40.5% to 14.8% during 33.9 months (range 0.4-143.6) median follow-up (3). For ERP, a similar result in the reduction of incontinence was observed in the current study as in previous studies in the literature (3,16,18). However, we did not observe worsening of the constipation as none of the patients with ERP had constipation symptoms before surgery. Also, no new onset constipation was observed during short-term follow-up in our study.

In this series, complex pelvic organ prolapse was present in 70% of the patients and for the diagnosis of complex pelvic organ prolapse, we chose to use dynamic MR defecography, which provides excellent morphological and functional information on the pelvic floor. In our study, at physical examination, 20 patients had rectocele and on dynamic MR defecography 17 patients showed at least two different forms of co-existing abnormalities. The current findings are consistent with a previous report by Mellgren et al., which suggested that rectocele, as a solitary finding, is rare and the frequency of associated pelvic abnormalities in patients with anorectal disorders is high (21). Therefore, the assessment of associated pelvic abnormalities is essential before planning surgery. Several studies have shown that surgical correction of single compartment could worsen or even trigger the symptoms of the untreated compartment (22-24). Therefore, a standard multicompartiment procedure is necessary for the treatment of multicompartiment pelvic organ prolapse, and LVMR helps to correct posterior and middle pelvic organ prolapse by the position of mesh since the anterior rectal fixation of mesh reinforces rectovaginal septum and provides some degree of suspension to the middle pelvic compartment (1). While follow-up did not exceed 3 months, the complex pelvic organ prolapse patients in our study showed significant improvement in constipation in the short-term. Although LVMR is increasingly being used in the treatment of such complex pelvic organ prolapse, there is a discrepancy in the literature about long-term functional outcome of the technique in patients with multicompartiment pelvic organ prolapse. van den Esschert has reported that during short-term follow-up, LVMR improved defecation problems of all patients

with ODS, whereas at late follow-up, one third of the patients described aggravation of ODS symptoms (25). Similarly, the long-term degradation of typical and associated symptoms after enterocele treatment by ventral rectopexy has been observed in various studies (26,27). In a recently published article of D'Hoore, the author has argued that patients who could benefit from LVMR for ODS must be more carefully selected because LVMR in patients with ODS and IRP may not provide significant improvement in terms of functional outcome (28). However, Oxford grading system helps to subclassify IRP, and the research of the Oxford Group has shown LVMR provide good functional outcome in patients with high-grade IRP and concomitant enterocele (12,29). In our series, WCS of a patient with high grade IRP improved from 22 to 7. In the same article, D'Hoore has also suggested that patients with significant perineal descent and a denervated pelvic floor do not respond to LVMR (28). In our series, we observed various degrees of perineal descensus in patients with rectocele. Although statistically significant improvement was found in short-term functional outcome following LVMR in rectocele patients with gynecologic organ prolapse (descending perineum, vaginal vault and uterovaginal prolapse), ODS symptoms did not improve after LVMR in 2 patients with severe perineal descensus on physical examination.

Several limitations about the study should be taken into account. The study includes a case series with a small sample size and single surgeon experience in a heterogeneous group of patients. The length of follow-up of this study is too short in order to assess the durability and complications of LVMR. Finally, this series is limited by its retrospective character.

CONCLUSION

Laparoscopic ventral mesh rectopexy appears a safe and effective procedure to correct ERP, high grade IRP and symptomatic rectocele with low morbidity rate and significant reduction of incontinence and constipation. Complex pelvic organ prolapse treatment by LVMR is also effective and is associated with a short-term good functional outcome, but we think that careful patient selection is mandatory for complex pelvic organ prolapse treatment by LVMR in order to prevent long-term degradation of the symptoms.

ACKNOWLEDGEMENTS

The author thank to Furuzan Kokturk, Assistant Professor of Department of Biostatistics, Faculty of Medicine, Zonguldak Bulent Ecevit University, for their contribution in the acquisition of data.

Ethics Committee Approval: Ethics committee approval was received for this study from the Ethics Committee of Zonguldak Bulent Ecevit University Clinical Research (2018/137).

Informed Consent: Written informed consent was obtained from patients who participated in this study.

Peer-review: Externally peer-reviewed.

Author Contributions: Consept - F.A.G.; Design - F.A.G.; Supervision - F.A.G.; Resource - F.A.G.; Materials - F.A.G.; Data Collection and/or Processing - F.A.G.; Analysis and Interpretation - F.A.G.; Literature Search - F.A.G.; Writing Manuscript - F.A.G.; Critical Reviews - F.A.G.

Conflict of Interest: The author declares that she has no conflict of interest.

Financial Disclosure: The authors declared that this study has received no financial support.

REFERENCES

1. D'Hoore A, Cadoni R, Penninckx F. Long-term outcome of laparoscopic ventral rectopexy for total rectal prolapse. *Br J Surg* 2004; 91: 1500-5. [\[CrossRef\]](#)
2. Mercer-Jones MA, D'Hoore A, Dixon AR, Lehur P, Lindsey I, Mellgren A, et al. Consensus on ventral rectopexy: report of a panel of experts. *Colorectal Dis* 2014; 16: 82-8. [\[CrossRef\]](#)
3. Consten EC, van Iersel JJ, Verheijen PM, Broeders IA, Wolthuis AM, D'Hoore A. Long-term outcome after laparoscopic ventral mesh rectopexy: an observational study of 919 consecutive patients. *Ann Surg* 2015; 262: 742-7. [\[CrossRef\]](#)
4. Formijne Jonkers HA, Poirri  N, Draaisma WA, Broeders IA, Consten EC. Laparoscopic ventral rectopexy for rectal prolapse and symptomatic rectocele: an analysis of 245 consecutive patients. *Colorectal Dis* 2013; 15: 695-9. [\[CrossRef\]](#)
5. Wong M, Meurette G, Abet E, Podevin J, Lehur PA. Safety and efficacy of laparoscopic ventral mesh rectopexy for complex rectocele. *Colorectal Dis* 2011; 13: 1019-23. [\[CrossRef\]](#)
6. Gouvas N, Georgiou PA, Agalianos C, Tan E, Tekkis P, Dervenis C, et al. Ventral colpoproctopexy for overt rectal prolapse and obstructed defaecation syndrome: a systematic review. *Colorectal Dis* 2015; 17: 034-046. [\[CrossRef\]](#)
7. Kim M, Meurette G, Ragu R, Lehur PA. Current surgical treatment of obstructed defecation among selected European opinion leaders in pelvic floor surgery. *Tech Coloproctol* 2016; 20: 395-9. [\[CrossRef\]](#)
8. D'Hoore A, Penninckx F. Laparoscopic ventral recto(colpo)pepy for rectal prolapse: surgical technique and outcome for 109 patients. *Surg Endosc* 2006; 20: 1919-23. [\[CrossRef\]](#)
9. Chandra A, Kumar S, Maurya AP, Gupta V, Gupta V, Rahul. Laparoscopic ventral mesh rectopexy for complete rectal prolapse: A retrospective study evaluating outcomes in North Indian population. *World J Gastrointest Surg* 2016; 27; 8: 321-5. [\[CrossRef\]](#)
10. Naeem M, Anwer M, Qureshi MS. Short term outcome of laparoscopic ventral rectopexy for rectal prolapse. *Pak J Med Sci* 2016; 32: 875-9. [\[CrossRef\]](#)
11. Ye GY, Wang Z, Matzel KE, Cui Z. Short-term outcomes of laparoscopic ventral rectopexy for obstructed defecation in patients with overt pelvic structural abnormalities-a Chinese pilot study. *Int J Colorectal Dis* 2017; 32: 1337-40. [\[CrossRef\]](#)
12. Wjffels NA, Collinson R, Cunningham C, Lindsey I. What is the natural history of internal rectal prolapse? *Colorectal Dis* 2010; 12: 822-30. [\[CrossRef\]](#)
13. Jorge JM, Wexner SD. Etiology and management of fecal incontinence. *Dis Colon Rectum* 1993; 36: 77-97. [\[CrossRef\]](#)
14. Agachan F, Chen T, Pfeifer J, Reissman P, Wexner SD. A constipation scoring system to simplify evaluation and management of constipated patients. *Dis Colon Rectum* 1996; 39: 681-5. [\[CrossRef\]](#)
15. Wong MT, Abet E, Rigaud J, Frampas E, Lehur PA, Meurette G. Minimally invasive ventral mesh rectopexy for complex rectocele: impact on anorectal and sexual function. *Colorectal Dis* 2011; 13: e320-326. [\[CrossRef\]](#)

16. Mackenzie H, Dixon AR. Proficiency gain curve and predictors of outcome for laparoscopic ventral mesh rectopexy. *Surgery* 2014; 156: 158-67. [CrossRef]
17. Gültekin FA, Wong MT, Podevin J, Barussaud ML, Boutami M, Lehur PA, et al. Safety of laparoscopic ventral rectopexy in the elderly: results from a nationwide database. *Dis Colon Rectum* 2015; 58: 339-43. [CrossRef]
18. Evans C, Stevenson AR, Sileri P, Mercer-Jones MA, Dixon AR, Cunningham C, et al. A multicenter collaboration to assess the safety of laparoscopic ventral rectopexy. *Dis Colon Rectum* 2015; 58: 799-807. [CrossRef]
19. Abed H, Rahn DD, Lowenstein L, Balk EM, Clemons JL, Rogers RG; Systematic Review Group of the Society of Gynecologic Surgeons. Incidence and management of graft erosion, wound granulation, and dyspareunia following vaginal prolapse repair with graft materials: a systematic review. *Int Urogynecol J* 2011; 22: 789-98. [CrossRef]
20. Smart NJ, Pathak S, Boorman P, Daniels IR. Synthetic or biological mesh use in laparoscopic ventral mesh rectopexy a systematic review. *Colorectal Dis* 2013; 15: 650-4. [CrossRef]
21. Mellgren A, Bremmer S, Johansson C, Dolk A, Udén R, Ahlbäck SO, al. Defecography: results of investigations in 2,816 patients. *Dis Colon Rectum* 1994; 37: 1133-41. [CrossRef]
22. Crafoord K, Sydsjö A, Johansson T, Brynhildsen J, Kjølhed P. Factors associated with symptoms of pelvic floor dysfunction six years after primary operation of genital prolapse. *Acta Obstet Gynecol Scand* 2008; 87: 910-5. [CrossRef]
23. Forsgren C, Zetterström J, Zhang A, Iliadou A, Lopez A, Altman D. Anal incontinence and bowel dysfunction after sacrocolpopexy for vaginal vault prolapse. *Int Urogynecol J* 2012; 21: 1079-84. [CrossRef]
24. Virtanen H, Hirvonen T, Mäkinen J, Kiilholma P. Outcome of thirty patients who underwent repair of posthysterectomy prolapse of the vaginal vault with abdominal sacral colpopexy. *J Am Coll Surg* 1994; 178: 283-7.
25. van den Esschert JW, van Geloven AA, Vermulst N, Groenedijk AG, de Wit LT, Gerhards MF. Laparoscopic ventral rectopexy for obstructed defecation syndrome. *Surg Endosc* 2008; 22: 2728-32. [CrossRef]
26. Jean F, Tanneau Y, Le Blanc-Louvry I, Leroi AM, Denis P, Michot F. Treatment of enterocele by abdominal colproctosacropexy efficacy on pelvic pressure. *Colorectal Dis* 2002; 4: 321-5. [CrossRef]
27. Oom DMJ, Van Dijk VRM, Gosselink MP, Van Wijk JJ, Schouten WR. Enterocele repair by abdominal obliteration of the pelvic inlet: long-term outcome on obstructed defaecation and symptoms of pelvic discomfort. *Colorectal Dis* 2007; 99: 845-50. [CrossRef]
28. D'Hoore A. Fine-tuning indications for laparoscopic ventral mesh rectopexy. *Tech Coloproctol* 2017; 21: 593-4. [CrossRef]
29. Ris F, Gorissen KJ, Ragg J, Gosselink MP, Buchs NC, Hompes R, et al. Rectal axis and enterocele on proctogram may predict laparoscopic ventral mesh rectopexy outcomes for rectal intussusception. *Tech Coloproctol* 2017; 21: 627-32. [CrossRef]



ORIJİNAL ÇALIŞMA-ÖZET

Türk J Surg 2019; 35 (2): 91-97

Rektal ve kompleks pelvik organ prolapsuslarında laparoskopik ventral mesh rektepeksinin kısa dönem sonuçları

Fatma Ayça Gültekin¹

¹ Zonguldak Bülent Ecevit Üniversitesi Tıp Fakültesi, Genel Cerrahi Anabilim Dalı, Zonguldak, Türkiye

ÖZET

Giriş ve Amaç: Laparoskopik ventral mesh rektepeksi (LVMR), eksternal rektal prolapsus (ERP), yüksek derece internal rektal prolapsus (İRP) ve rektosel gibi pelvik taban hastalıklarının tedavisinde daha çok kullanılır hale gelmiştir. LVMR ayrıca pelvik organ prolapsuslarının da tedavisine olanak sağlamaktadır. Bu çalışmada LVMR'nin, rektal ve kompleks pelvik organ prolapsuslarında güvenlik etkinlik ve kısa dönem fonksiyonel sonuçları incelenmiştir.

Gereç ve Yöntem: Şubat 2014-Ekim 2017 tarihleri arasında LVMR yapılan tüm hastalar çalışmaya dahil edilmiştir. Hastalar preoperatif ve postoperatif 3. ayda değerlendirilmiştir. Cerrahi komplikasyonlar ve fonksiyonel sonuçlar; fekal inkontinans, Wexner inkontinans Skoru (WIS) ve konstipasyon, Wexner Konstipasyon Skoru (WKS) ile değerlendirilmiştir.

Bulgular: Otuz hastaya (4'ü erkek) LVMR yapılmıştır. On yedi (56,6%) hastada dinamik-Mr defekografi bulgularına göre kompleks pelvik organ prolapsusunun olduğu tespit edilmiştir. Ortalama operasyon ve hastanede kalış süreleri 110 dakika ve 4 gündür. Mesh komplikasyonu veya rekürrens izlenmemiştir. Preoperatif 21 (%70) hastada obstrüktif defekasyon yakınmaları olduğu tespit edilmiş olup, WKS'nin median 19'dan postoperatif 3. ayda 6'ya düştüğü görülmüştür ($p < 0,001$). Preoperatif WIS'in hesaplandığı ve median 14 olduğu 9 hastada postoperatif 3. ayda 6'ya düştüğü saptanmıştır ($p = 0,008$). Semptomatik rektosel ile birlikte enterosel ve sigmoidoseli olan hastalarda da WKS LVMR sonrası anlamlı derecede düzeldiği görülmüş ($p = 0,005$) ve ayrıca anlamlı düzelmeye semptomatik rektosel ve beraberinde jinekolojik organ prolapsusu olan hastalarda da izlenmiş; preoperatif median WKS'nin 18'den postoperatif 8'e gerilemiştir ($p = 0,005$).

Sonuç: Serimizdeki hastalarda kısa dönem takiplerde LVMR'nin, etkili bir cerrahi seçenek olduğu tespit edilmiştir.

Anahtar Kelimeler: Rektal prolaps, pelvik organ prolaps, laparoskopik ventral rektepeksi

DOI: 10.5578/turksurg.4157