

Single-incision laparoscopic adrenalectomy in a patient with acute hypokalemic paralysis due to primary hyperaldosteronism

Primer hiperaldosteronizme bağlı akut hipokalemik paralizili bir hastada tek insizyondan laparoskopik adrenalektomi

Lütfi Soylu¹, Oğuz Uğur Aydın¹, Mustafa Cesur², Serdar Özbaş¹, Selçuk Hazinedaroğlu³

ABSTRACT

Acute hypokalemic paralysis is a relatively rare cause of acute weakness. It may resolve spontaneously; however, it may be a potential life-threatening condition. Hypertension may be considered the most important finding in combination with hypokalemic paralysis for raising the suspicion of primary hyperaldosteronism (PHA). A 55-year-old hypertensive Mexican woman was admitted to the Emergency Unit with a sudden onset of generalized paralysis. An endocrinological workup and an abdominal magnetic resonance imaging revealed PHA with a 1.5 cm left adrenal tumor. After preoperative medication, left adrenalectomy was performed with single-incision laparoscopic surgery (SILS). The duration of the surgery was 45 min, and no postoperative complication was encountered. The patient was discharged after 24 h. Hypokalemic paralysis may be due to different conditions, but it may raise the suspicion of PHA in combination with a history of generally mild hypertension. Laparoscopic adrenalectomy is the preferred operation for unilateral adrenal adenomas that cause PHA. Single-incision laparoscopic surgery is a step-forward technique that improves the cosmesis, decreases access-related morbidity, and increases the postoperative recovery. We report a case with acute hypokalemic paralysis due to PHA and treated with SILS.

Keywords: Hypokalemic paralysis, hypokalemia, single-incision laparoscopic surgery

ÖZET

Akut hipokalemik paralizisi; akut güçsüzlüğün relatif olarak az görülen bir sebebidir. Spontan olarak gerilemekle beraber hayatı tehdit eden bir problem olabilir. Hipertansiyon akut hipokalemik paralizisi ile beraber en önemli bulgu olabilir. Elli beş yaşında kadın hasta ani başlayan paralizisi ile acil servise başvurdu. Endokrinoloji değerlendirmesi ve abdominal magnetik rezonans görüntüleme primer hiperaldosteronizm (PHA) ile beraber sol adrenal bezde 1,5 cm'lik tümör tespit etti. Hastaya tek insizyondan laparoskopik cerrahi ile sol adrenalektomi gerçekleştirildi. Ameliyat süresi 45 dakika idi ve herhangi bir komplikasyon olmadı. Hasta 24 saat sonra taburcu edildi. Hipokalemik paralizinin farklı sebepleri olabilir fakat ılımlı hipertansiyon öyküsü PHA'den şüphelendirir. Primer hiperaldosteronizme yol açan tek taraflı adrenal adenomlarında laparoskopik adrenalektomi tercih edilen cerrahi yöntemdir. Tek insizyondan laparoskopik cerrahi; kozmetik sonuçları daha iyi, düşük morbiditeye sahip, postoperatif derlenmeyi çabuklaştıran bir tekniktir. Biz burada tek insizyondan laparoskopik cerrahi ile tedavi edilen PHA'ye bağlı akut hipokalemik paralizili bir hastayı sunduk.

Anahtar Kelimeler: Hipokalemik paralizisi, hipokalemi, tek insizyondan laparoskopik cerrahi

INTRODUCTION

Primary hyperaldosteronism (PHA) involves the hypersecretion of the mineralocorticoid aldosterone due to adrenal gland pathology (mostly unilateral adrenal adenoma). It increases the excretion of potassium and hydrogen ions via urine; mild retention of sodium and water in the body; and results in hypokalemia, mild hypertension, and metabolic alkalosis. Hypokalemic weakness either presents in the form of persistent or acute paralysis, a common symptom of PHA. Hypokalemia is generally well tolerated in otherwise healthy people, but it can be life-threatening when severe (1). Hypokalemic paralysis (HP) may be due to different conditions, but it may raise the suspicion of PHA in combination with hypertension.

Hypokalemic paralysis may either be periodic or not and can be classified as hypokalemic periodic paralysis (HPP) and hypokalemic nonperiodic paralysis (HNP) (2). Lin et al. (2) previously termed non-hypokalemic periodic paralysis instead of HNP, but we prefer the second term for nomenclature because Williams et al. (3) have used it recently. The acute shift of potassium into cells is the main etiological factor in HPP, while hypokalemia and paralysis are generally caused by excessive excretion and depletion of potassium in HNP (2).

We have to mention that sometimes HP may be the first manifestation of HPP without any periodic attacks, while HNP may have episodes of HP. Very recently, Hiraga et al. (4) have employed the term acquired non-thyrotoxic hypokalemic paralysis (ANHP) in place of HNP. From our point of view, this is the best term which meets all criteria, and also thyrotoxic hypokalemic paralysis (THP) is better than thyrotoxic hypokalemic periodic paralysis. There is a growing interest in minimal invasive surgical techniques. The number of procedures utilizing surgical methods such as single-incision laparoscopic surgery (SILS) and natural orifice transluminal endoscopic surgery (NOTES) is gradually increasing. Laparoscopic im-

¹Clinic of General Surgery, Private Ankara Güven Hospital, Ankara, Turkey

²Clinic of Endocrinology, Private Ankara Güven Hospital, Ankara, Turkey

³Department of General Surgery, Ankara University Faculty of Medicine, Ankara, Turkey

Address for Correspondence Yazışma Adresi

Lütfi Soylu

Özel Ankara Güven Hastanesi,
Genel Cerrahi Kliniği, Ankara,
Türkiye

Phone: +90 312 457 24 81

e-mail: lutfisoylu@hotmail.com

Received / Geliş Tarihi: 18.02.2015

Accepted / Kabul Tarihi: 02.04.2015

Available Online Date /

Çevrimiçi Yayın Tarihi: 14.07.2015

©Copyright 2015

by Turkish Surgical Association

Available online at

www.ulusalcerahidergisi.org

©Telif Hakkı 2015

Türk Cerrahi Derneği

Makale metnine

www.ulusalcerahidergisi.org

web sayfasından ulaşılabilir.

plementations are preferred as an alternative method to open surgeries because the complication rate and post-operative pain are low, better cosmetic results are obtained, and patients return to their everyday life earlier (5).

Single-port or SILS is a current development in minimal invasive surgery. This approach is based on inserting all laparoscopic equipment from a single incision on the abdominal wall. After single incision, the operation is performed by entering from the fascial plans under the single port made for this method or under the same skin incision.

Herein, we report a case with acute HP due to PHA with a left adrenal adenoma and treated with SILS.

CASE PRESENTATION

A 55-year-old Mexican woman was admitted to the Emergency Unit with a sudden onset of general paralysis during her holiday trip to Turkey. No predisposing factors for paralysis were present. She had no previous attack before and there was no known family history of periodic paralysis. On physical examination, her blood pressure was 160/90 mm - Hg, and her pulse was 86 bpm and regular. Her weight was normal with a body mass index of 22.2 kg/m². Her muscle strength was found to be 4/5 in distal, 3/5 in proximal upper extremities, bilaterally. The deep tendon reflexes were hypoactive. In her medical history, she had a serious hypertensive attack and a multi-drug antihypertensive regimen was administered (olmesartan/hctz: 40/12.5 mg 1×1 and amlodipine 10 mg 1×1 in a day).

On laboratory examination, serious hypokalemia was diagnosed (potassium level: 1.35 mEq/L). She had signs of grade I hypertensive retinopathy and grade I diffuse euthyroid enlargement. There was no pathological finding in the cranial computed tomography (CT). Normal calcium, phosphorous, and magnesium levels were found, while there were high creatine phosphokinase levels (1029 U/L) and metabolic alkalosis. Thyroid function tests were in normal limits. Hypokalemia was attributed as the reason of paralysis.

Then, the patient was hospitalized and transferred to the Endocrinology Department. After obtaining the patient's informed consent, intravenous (IV) potassium replacement therapy was started and totally 600 mEq of KCl was administered in 48 h. Her potassium level increased to 2.7 mEq/L. Magnetic resonance imaging examination was performed to observe the adrenal glands, and an adenoma with a diameter of 1.5 cm was found in her left side (Figure 1). The aldosterone/plasma renin activity ratio (A/PRA) was 200. For confirmation of hyperaldosteronism, the salt loading test was performed (Table 1). During the test, the basal A/PRA ratio was 323, and it decreased to only 23.75 after salt loading. In normal subjects, it must decrease to below 10.

The patient was diagnosed with PHA (Conn syndrome) based on the left adrenal mass observed in MRI images and hormone levels. An operation on the left adrenal mass by the laparoscopic method was planned. Spironolactone (Aldactone; 100 mg 1×1), olmesartanHCl (Olmetec; 20 mg 1×1), and potassium citrate + carbonate (Kalinor; 8 mg 2×1) effervescent tablets were started in the preoperative period.

Table 1. The list of the hormone and electrolyte levels during illness and wellness periods

Date	State	A	PRA	A/PRA	K	Na
Day 1	Before K Infusion	-	-	-	1.35	142
Day 2	During K Infusion	44	0.22	200	2.22	148
Day 4	Before salt loading test	48.5	0.15	323	2.62	145
Day 4	After salt loading test	38	1.6	23.75	-	-
Day 15	Before operation after SPNL	65	13.7	4.7	4.64	134
Day 16	After operation	6.4	1.8	3.56	4.79	135

A: aldosterone; PRA: plasma renin activity; SPNL: spironolactone

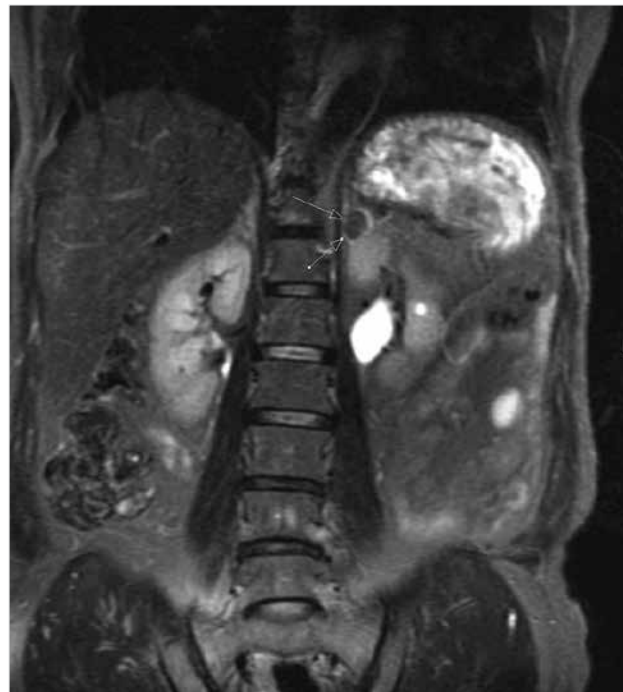


Figure 1. Magnetic resonance imaging examination revealed an adenoma with a diameter of 1.5 cm in the left adrenal gland

Surgical technique: The surgical team had previously conducted more than 200 laparoscopic donor nephrectomies and more than 50 laparoscopic adrenalectomies. After the anesthetic induction, the patient was positioned in a right semi-lateral position. A 2.5 cm incision was made to the left lateral side of the umbilicus and a 3-channel single port was placed through this incision with an open technique (SILS port, Covidien). Pneumoperitoneum was obtained through carbon dioxide insufflation by ensuring 14 mm-Hg pressure from the channel on port. Two 5 mm laparoscopic trocars and a 10 mm camera with 30° angle were placed through the ports (Figure 2). The splenic flexure of the colon and the spleen was mobilized with the help of an ultrasonic dissector. During the procedure, an endoscopic retractor or a loop retractor was not required. The left main adrenal vein was clipped and cut with the help of an ultrasonic dissector. The left adrenal gland was completely mobilized with the help of an ultrasonic dissector and extracted by the simultaneous removal of the endobag and SILS port. No drain was inserted. The fascia was closed us-

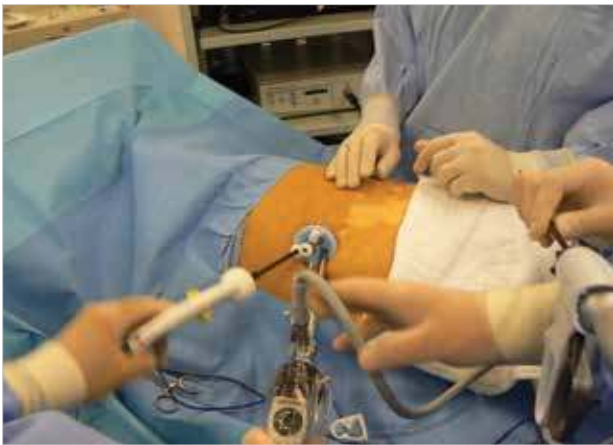

Figure 2. Left adrenalectomy performed with the single-incision laparoscopic surgery procedure

ing polypropylene sutures (number-0), and the procedure was completed by closing the skin using the 3/0 polypropylene suture (Ethicon). The operation time was 45 min.

No complications occurred during the postoperative follow-up period. After 6 h, she was able to eat. Postoperative analgesia was ensured through a single dose of 100 mg of diclofenac sodium. She was normotensive and normokalemic without any medication after the operation. The list of preoperative and postoperative hormone and electrolyte levels are given in Table 1. She was discharged after 24 h, and her satisfaction with postoperative pain and the incision was high. Pathological evaluation demonstrated an adrenal adenoma.

DISCUSSION

Hypokalemia is generally well tolerated in otherwise healthy people, but it can be life-threatening when severe. On the other hand, the clinical symptoms of PHA are often absent or non-specific. Spontaneous hypokalemia in a patient with a generally mild hypertension is a strong indicator for PHA. Hypokalemia can be defined as a serum potassium level below 3.5 mEq/L. The major outcomes of severe hypokalemia result from its effects on nerves and muscles, including the heart muscle (6). When severe hypokalemia develops in which serum potassium levels are less than 2.5 mEq/L, generalized weakness and dangerous ventricular tachyarrhythmias may occur. An acute decrease of serum potassium levels may be more arrhythmogenic than chronic hypokalemia (7, 8). Although there are extensive potential causes in the differential diagnosis of hypokalemia, the etiological factors for acute HP are less (9).

Treatment of hypokalemia immediately with potassium supplementation provides rapid improvement of clinical symptoms. Spironolactone is a preferable drug in the postoperative period for maintaining normokalemia. The goal of the therapy will be to normalize serum potassium levels and treatment of the underlying disease. Surgical treatment of primary aldosteronism is the definitive therapy of HP induced by Conn's syndrome; therefore, the serious events that hypertension and paralysis trigger will be prevented (7). After surgery, our patient was cured for both hypertension and HP.

The first laparoscopic appendectomy was performed by Semm in 1983, and the first laparoscopic cholecystectomy was

performed by Mouret in 1987. Subsequently, the frequency of advanced laparoscopic surgeries has increased. For the last 30 years, laparoscopic implementations have been successfully applied in the treatment of many diseases and in many branches.

Single-incision laparoscopic surgery implementation is a recent method. Many operations, such as cholecystectomy, adrenalectomy, laparoscopic total extraperitoneal inguinal hernia treatment, right hemicolectomy, left hemicolectomy, rectum operations, sleeve gastrectomy, gastrojejunostomy, and nephrectomy have been performed through a single incision. The literature includes some cases of SILS adrenalectomy (10). During single-port or single-incision surgery, the surgeon may have to cross handle tools to ensure correct angles, which may cause the operations to last longer in the first cases. Within the last few years, devices have been developed for SILS and have become more flexible; the development of lockable models has also allowed operations to be conducted more easily.

We believe that SILS adrenalectomy can easily be applied in weak patients and small diameter tumors. Generally, adrenal glands cannot be entirely removed from the abdomen through 5 mm incisions in classical adrenalectomy; therefore, the incision may have to be extended. On the other hand, in SILS adrenalectomy, the adrenal adenoma is removed via an alternative incision to the port without any need to extend the present incision.

Single-incision laparoscopic surgery procedures have recently become more common worldwide and undoubtedly suppressed standard laparoscopy. In particular, with respect to cosmetic purposes, SILS is seen as an alternative to conventional methods. However, the results of prospective randomized studies should be undertaken, evaluating prospective pain, complications associated with port location, cosmetic outcomes, length of hospital stay, and patient satisfaction. Single-incision laparoscopic surgery adrenalectomy is a safe procedure for the removal of a benign adrenal lesion when performed by an experienced surgeon.

CONCLUSION

We report a case with acute HP due to PHA and treated with SILS. Hypokalemic paralysis may be due to different conditions, but it may raise the suspicion of PHA in combination with a history of generally mild hypertension. Laparoscopic adrenalectomy is the preferred operation for unilateral adrenal adenomas that cause PHA. Single-incision laparoscopic surgery is a step-forward technique that improves the cosmesis, decreases access-related morbidity, and increases the postoperative recovery.

Informed Consent: Written informed consent was obtained from patient who participated in this case.

Peer-review: Externally peer-reviewed.

Author Contributions: Concept - L.S.; Design - O.U.A.; Supervision - M.C., S.H., S.Ö.; Funding - L.S., M.C.; Data Collection and/or Processing - O.U.A., S.Ö.; Analysis and/or Interpretation - L.S., M.C., O.U.A., S.H.; Literature Review - L.S., O.U.A.; Writer - L.S.; Critical Review - L.S., O.U.A., M.C.; Other - S.Ö., S.H.

Conflict of Interest: No conflict of interest was declared by the authors.

Financial Disclosure: The authors declared that this study has received no financial support.

Hasta Onamı: Yazılı hasta onamı bu olguya katılan hastadan alınmıştır.

Hakem Değerlendirmesi: Dış bağımsız.

Yazar Katkıları: Fikir - L.S.; Tasarım - O.U.A.; Denetleme - M.C., S.H., S.Ö.; Kaynaklar - L.S., M.C.; Veri toplanması ve/veya işlemesi - O.U.A., S.Ö.; Analiz ve/veya yorum - L.S., M.C., O.U.A., S.H.; Literatür taraması - L.S., O.U.A.; Yazıyı yazan - L.S.; Eleştirel inceleme - L.S., O.U.A., M.C.; Diğer - S.Ö., S.H.

Çıkar Çatışması: Yazarlar çıkar çatışması bildirmemişlerdir.

Finansal Destek: Yazarlar bu çalışma için finansal destek almadıklarını beyan etmişlerdir.

REFERENCES

1. Cesur M, Ilgin SD, Baskal N, Gullu S. Hypokalemic paralysis is not just a hypokalemic paralysis. *Eur J Emerg Med* 2008; 15: 150-153. [\[CrossRef\]](#)
2. Lin SH, Lin YF, Halperin ML. Hypokalaemia and paralysis. *QJM* 2001; 94: 133-139. [\[CrossRef\]](#)
3. Williams DT, Smith RS, Mallon WK. Severe hypokalemia, paralysis, and AIDS-associated isospora belli diarrhea. *J Emerg Med* 2011; 41: e129-132. [\[CrossRef\]](#)
4. Hiraga A, Kamitsukasa I, Kojima K, Kuwabara S. Clinical features and recovery patterns of acquired non-thyrototoxic hypokalemic paralysis. *J Neurol Sci* 2012; 313: 42-45. [\[CrossRef\]](#)
5. Maartense S, Bemelman WA, Gerritsen vander Hoop A, Meijer DW, Gouma DJ. Hand assisted laparoscopic surgery (HALS): a report of 150 procedures. *Surg Endosc* 2004; 3: 397-401. [\[CrossRef\]](#)
6. ECC Committee, Subcommittees and Task Forces of the American Heart Association. American Heart Association Guidelines for Cardiopulmonary Resuscitation and Emergency Cardiovascular Care. *Circulation* 2005; 13: 112: IV1-203.
7. Rastegar A, Soleimani M. Hypokalaemia and hyperkalaemia. *Postgrad Med J* 2001; 77: 759-764. [\[CrossRef\]](#)
8. Reddy VG. Potassium and anaesthesia. *Singapore Med J* 1998; 39: 511-516.
9. Stedwell RE, Allen KM, Binder LS. Hypokalemic paralyses: a review of the etiologies, pathophysiology, presentation, and therapy. *Am J Emerg Med* 1992; 10: 143-148. [\[CrossRef\]](#)
10. Walz MK, Groeben H, Alesina PF. Single-access retroperitoneal adrenalectomy (SARA) versus conventional retroperitoneoscopic adrenalectomy (CORA): a case-control study. *World J Surg* 2010; 34: 1386-1390. [\[CrossRef\]](#)