

Giant multicystic malignant pheochromocytoma

Dev multikistik malign feokromasitoma

Erdal Uysal¹, Turkey Kırdak², Ahmet Orhan Güner¹, Mehmet Ali İkiadağ³

ABSTRACT

Pheochromocytoma is a rare tumor originating from the embryonic neural crest and secreting high levels of catecholamines. The average tumor size is approximately 7 cm, and the average weight is approximately 200 g in the previous publications. Sometimes these tumors may be bigger. In this report, a case of multicystic malignant pheochromocytoma with a huge size is presented, which is seldom reported in the past. A 37-year-old male patient was referred to our hospital for etiological investigation of his recently diagnosed hypertension. Contrast-enhanced computed tomography (CT) examination was performed for further evaluation of the lesion and surrounding tissues. The lesion was 18 × 8 × 13 cm in size. It had lobulated margins, large cystic components, and peripheral and septal contrast enhancement. The levels of metanephrine, normetanephrine, adrenaline, noradrenaline, vanilmandelic acid, and dopamine were significantly elevated. The patient was prepared for surgery. In the pathological evaluation, the mass weighed 1018 g and was 18 × 8 × 13 cm in size. He was diagnosed with malignant pheochromocytoma. After eight months, a CT examination showed a recurrent mass, liver metastasis, and distant metastasis. The patient received chemotherapy and radiotherapy. Multicystic malignant pheochromocytoma may reach huge sizes without causing any symptoms.

Keywords: Giant, malignant, pheochromocytoma

ÖZET

Feokromasitoma, embriyonik nöral krestten köken alan ve yüksek miktarda katekolamin salgılayan nadir görülen bir tümördür. Daha önceki yayınlarda ortalama tümör boyutu 7 cm ve ortalama ağırlık 200 gram olarak bildirilmiştir. Bazen bu tümörler daha büyük olabilir. Bu sunumda daha önce nadiren bildirilen multikistik malign dev feokromasitomali olgu sunulmuştur. Otuz yedi yaşında erkek hasta, yeni tanı konulmuş hipertansiyonun etiyolojik incelemesi nedeniyle hastanemize gönderilmişti. Lezyonun ve çevre dokunun ileri değerlendirilmesi için kontrastlı bilgisayarlı tomografi (BT) yapıldı. Lobule kenarlı, geniş kistik komponentler içeren periferik ve bölümsel kontrast artışı olan 18 x 8 x 13 cm büyüklüğünde lezyon vardı. Metanefrin, normetanefrin, adrenalin, noradrenalin, vanil mandelik asit ve dopamin miktarları önemli derecede yükselmisti. Hasta cerrahi girişim için hazırlandı. Patolojik incelemede kitlenin ağırlığı 1018 gr, boyutu 18 x 8 x 13 cm büyüklüğündeydi. Tanı malign feokromasitoma idi. Sekiz ay sonra BT incelemede nüks kitle, karaciğer ve uzak metastazlar vardı. Hasta kemoterapi ve radyoterapi aldı. Multikistik malign feokromasitoma hiçbir semptomla sebep olmadan dev boyutlara ulaşabilir.

Anahtar Kelimeler: Dev, malign, feokromasitoma

¹Department of General Surgery, Sanko University, Gaziantep, Turkey

²Department of General Surgery, Uludağ University Faculty of Medicine, Bursa, Turkey

³Department of Radiology, Sanko University, Gaziantep, Turkey

Address for Correspondence Yazışma Adresi

Erdal Uysal

Sanko Üniversitesi, Genel Cerrahi
Anabilim Dalı, Gaziantep, Türkiye
Phone: +90 342 211 50 00
e-mail: drerdaluyisal@hotmail.com

Received / Geliş Tarihi: 02.12.2014

Accepted / Kabul Tarihi: 28.02.2015

Available Online Date /

Çevrimiçi Yayın Tarihi: 14.07.2015

©Copyright 2015

by Turkish Surgical Association

Available online at

www.ulusalcerahidergisi.org

©Telif Hakkı 2015

Türk Cerrahi Derneği

Makale metnine

www.ulusalcerahidergisi.org

web sayfasından ulaşılabilir.

INTRODUCTION

Pheochromocytoma is a rare tumor originating from the embryonic neural crest and secreting high levels of catecholamines (1). Though it may remain silent, it usually causes clinical symptoms such as headache, palpitation, and hypertension due to these secretions. Asymptomatic cases may have a late diagnosis. The average tumor size is approximately 7 cm, and the average weight is approximately 200 g in the previous publications (2). Sometimes these tumors may be bigger (1, 3-8). In this report, a case of multicystic malignant pheochromocytoma with a huge size is presented, which is seldom reported in the past.

CASE PRESENTATION

A 37-year-old male patient was referred to our hospital for etiological investigation of his recently diagnosed hypertension. In his physical examination, a bulky mass was palpated in the left upper quadrant. Blood electrolyte and glucose levels, haemogram, and other biochemical parameters were unremarkable. Ultrasound examination showed a huge multicystic mass lesion in the left adrenal gland, next to the left kidney. Contrast-enhanced computed tomography (CT) was performed for further evaluation of the lesion and surrounding tissues. The lesion was 18 cm×8 cm×13 cm in size. It had lobulated margins, large cystic components and peripheral and septal contrast enhancement. The tail of the pancreas and spleen was anteriorly displaced, and the left kidney was inferiorly displaced. The left adrenal gland was not visible apart from this lesion. Minimally abdominal free fluid was noted; the right adrenal gland was normal, and there was no finding of distant metastasis. There was no evidence of invasion and lymphadenopathy (Figure 1).

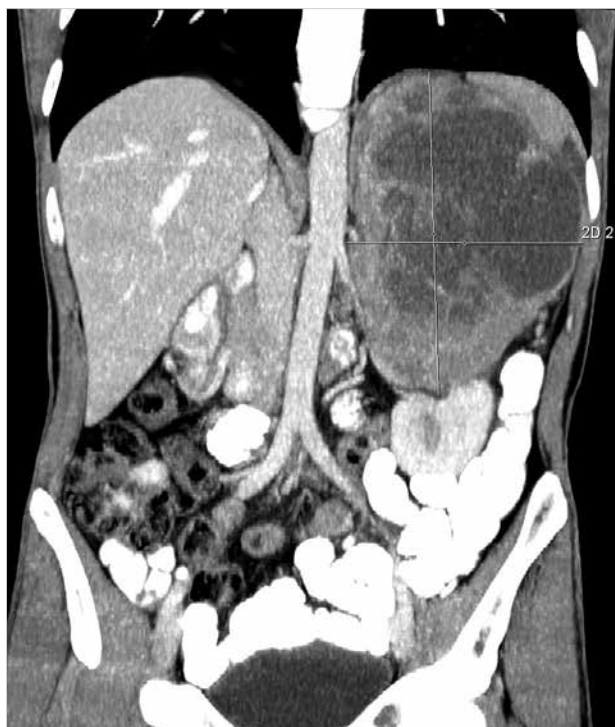


Figure 1. Large pheochromocytoma on computed tomography (coronal section)

Twenty-four hour urine catecholamine levels were studied. The levels of metanephrine, normetanephrine, adrenaline, noradrenaline, vanilmandelic acid, and dopamine were significantly elevated. The 24 h urine levels of metanephrine, normetanephrine, vanilmandelic acid, homovanillate, epinephrine, norepinephrine, and dopamine were 2195 mg/24 h (0–320 mg/24 h), 3707 mg/24 h (0–390 mg/24 h), 33 mg/24 h (1.7–6.5 mg/24 h), 23 mg/24 h (2–7.4 mg/24 h), 65 mg/24 h (1–27 mg/24 h), 154 mg/24 h (1–97 mg/24 h), and 1719 mg/24 h (1–500 mg/24 h), respectively. Blood cortisol level was normal. Blood parathyroid hormone and calcitonin levels were normal. Family history was negative with regards to multiple endocrine neoplasia (MEN) syndrome. The diagnosis of a possibly malignant pheochromocytoma was made. The patient was prepared for surgery; median incision was performed for exploration. The lesion had a close relation to the left lobe of the liver, left kidney, and tail of the pancreas, but there was no invasion. The mass was totally resected. Perioperative or postoperative complication did not develop. The patient was discharged from the hospital on the seventh postoperative day. In the pathological evaluation, the mass weighted 1018 g and was 18 × 8 × 13 cm in size. It showed a high mitotic index and capsular and vascular invasion, and the abdominal fluid sample showed atypical cells leading to the diagnosis of malignant pheochromocytoma. Postoperative ¹³¹I-metaiodobenzylguanidine (MIBG) was administered for treatment. After eight months, a CT examination showed a recurrent mass, which was 12 cm, in the left adrenal gland. There were two liver metastases; one was 9 cm and the other was 1.5 cm in size. Additionally, he had multiple para-aortic, perirenal, and perisplenic enlarged lymph nodes and a small metastatic nodule in the right adrenal gland. There were distant metastases in both lungs and multiple bones, including the lumbosacral vertebrae and right iliac bone on CT. The patient received chemotherapy and radiotherapy. Our patient died eleven months after surgery.

Table 1. Pheochromocytomas reported to be larger than 16 cm

Author/ year	Sex/ age	Country	Size (cm)	Lap/ open	Recur- rence	Survival
Grissom et al. (4)	F/54	USA	45×25	Open	Unknown	Unknown
Costa et al. (5)	M/46	Brazil	30	Open	No	Died
Suga et al. (3)	M/48	Japan	21×13	Open	No	Yes
Melegh et al. (6)	M/55	Hungary	20	Open	Unknown	Unknown
Ambati et al. (1)	F/77	Canada	19×12×18	Open	No	Yes
Pan et al. (7)	M/46	USA	18×14×13	Open	No	Yes
Current case	M/37	Turkey	18×13	Open	Yes	Died
Costa et al. (5)	F/43	Brazil	18	Open	Yes	Yes
Daughtry et al. (8)	M/53	USA	17	Open	Unknown	Unknown

F: female; M: male; Lap: laparoscopic

DISCUSSION

Most pheochromocytomas are benign and approximately 10% have malignant behavior (1). With increasing size, the probability of malignancy becomes higher; in lesions over 6 cm, the ratio of benign-to-malignant tumors is 1:8 (9). The average tumor size is approximately 7 cm (2). There are only few reports of huge multicystic malignant pheochromocytoma above 18 cm, and to our knowledge, the pheochromocytoma in this case is the largest one reported from our country (1, 3–8). Seven giant pheochromocytomas larger than 16 cm in current literature have been documented (Table 1). Classical symptoms of pheochromocytoma include headache, palpitation, and hypertension. Some cases may not show any symptoms. The sole reason for the admission of our patient was hypertension. In our case, the lack of prominent symptoms may have resulted in the tumor reaching huge sizes and the late diagnosis.

Histopathologically, it is not always possible to distinguish benign lesions from malignant ones that do not have an accompanying metastatic lesion or invasion. The presence of capsular and vascular invasion, distant metastasis, high mitotic index and proliferative activity, intra-abdominal malignant-free fluid, and postoperative local recurrence are features of malignancy. Immunohistochemical analysis may be necessary to support the diagnosis. The role of the laparoscopic approach for large tumors is still controversial. In a study, lesion sizes of 12 cm to 14 cm have been cited as the upper limit for laparoscopic adrenalectomy (10). In our case, considering the large size of the tumor and possible malignancy with local invasion, we preferred traditional open surgery. There are not enough studies on the prognosis and survival of malignant pheochromocytoma because of its lower incidence. Malignant pheochromocytoma usually has a poor prognosis and resistance to chemotherapy and radiotherapy. The administration

of 131-I-MIBG and long-acting octreotide in patients who are somatostatin receptor positive can be used in the treatment of malignant pheochromocytoma. In patients with metastatic pheochromocytoma, long-term survival is possible; the overall five-year survival; however, is less than 50%.

When the cases in Table 1 were evaluated, the largest pheochromocytoma in the world was reported to be 45 cm. All patients were operated with the open method. Two cases were benign and six were malignant. One case was uncertain. Mortality and recurrence developed in two malignant cases.

CONCLUSION

Multicystic malignant pheochromocytoma may reach huge sizes without causing any symptoms.

Informed Consent: Written informed consent was obtained from patient who participated in this case.

Peer-review: Externally peer-reviewed.

Author Contributions: Concept - E.U., T.K., A.O.G., M.A.İ.; Design - E.U., T.K., A.O.G., M.A.İ.; Supervision - E.U., T.K., A.O.G., M.A.İ.; Funding - E.U., T.K.; Materials - E.U., T.K., M.A.İ.; Data Collection and/or Processing - E.U., T.K., M.A.İ.; Analysis and/or Interpretation - E.U., T.K., A.O.G., M.A.İ.; Literature Review - E.U., T.K., A.O.G.; Writer - E.U., T.K., M.A.İ.; Critical Review - E.U., T.K., A.O.G.

Conflict of Interest: No conflict of interest was declared by the authors.

Financial Disclosure: The authors declared that this study has received no financial support.

Hasta Onamı: Yazılı hasta onamı bu olguya katılan hastadan alınmıştır.

Hakem Değerlendirmesi: Dış bağımsız.

Yazar Katkıları: Fikir - E.U., T.K., A.O.G., M.A.İ.; Tasarım - E.U., T.K., A.O.G., M.A.İ.; Denetleme - E.U., T.K., A.O.G., M.A.İ.; Kaynaklar - E.U., T.K.; Malzemeler - E.U., T.K., M.A.İ.; Veri toplanması ve/veya işlemesi - E.U., T.K.,

M.A.İ.; Analiz ve/veya yorum - E.U., T.K., A.O.G., M.A.İ.; Literatür taraması - E.U., T.K., A.O.G.; Yazıyı yazan - E.U., T.K., M.A.İ.; Eleştirel inceleme - E.U., T.K., A.O.G.

Çıkar Çatışması: Yazarlar çıkar çatışması bildirmemişlerdir.

Finansal Destek: Yazarlar bu çalışma için finansal destek almadıklarını beyan etmişlerdir.

REFERENCES

1. Ambati D, Jana K, Domes T. Largest pheochromocytoma reported in Canada: A case study and literature review. *Can Urol Assoc J* 2014; 5-6: E374-377. [\[CrossRef\]](#)
2. Thompson LD. Pheochromocytoma of the Adrenal gland Scaled Score (PASS) to separate benign from malignant neoplasms: a clinicopathologic and immunophenotypic study of 100 cases. *Am J Surg Pathol* 2002; 26: 551-566. [\[CrossRef\]](#)
3. Suga K, Motoyama K, Hara A, Kume N, Ariga M, Matsunaga N. Tc-99m MIBG imaging in a huge clinically silent pheochromocytoma with cystic degeneration and massive hemorrhage. *Clin Nucl Med* 2000; 25: 796-800. [\[CrossRef\]](#)
4. Grissom JR, Yamase HT, Prosser PR. Giant pheochromocytoma with sarcoidosis. *South Med J* 1979; 72: 1605-1607. [\[CrossRef\]](#)
5. Costa SRP, Cabral NM, Abhrão AT, Costa RB, Silva LM, Lupinacci RA. Giant cystic malignant pheochromocytoma invading right hepatic lobe: Report on two cases. *Sao Paulo Med J* 2008; 26: 229-231. [\[CrossRef\]](#)
6. Melegh Z, Rényi-Vámos F, Tanyay Z. Giant cystic pheochromocytoma located in the renal hilus. *Pathol Res Pract* 2002; 198: 103-106. [\[CrossRef\]](#)
7. Pan Z, Repertinger S, Deng C, Sharma P. A giant cystic pheochromocytoma of the adrenal gland. *Endocr Pathol* 2008; 19: 133-138. [\[CrossRef\]](#)
8. Daughtry JD, Susan LP, Straffon RA, Stewart BH. A case of a giant pheochromocytoma. *J Urol* 1977; 118: 840-842.
9. Alexandraki KI, Grossman AB. Adrenal incidentalomas: 'the rule of four'. *Clin Med* 2008; 8: 201-204. [\[CrossRef\]](#)
10. Zografos GN, Kothionidis K, Ageli C, Kopanakis N, Dimitriou K, Papaliodi E, et al. Laparoscopic resection of large adrenal ganglioneuroma. *JSLs* 2007; 11: 487-492.