

A rare case: Retrocecal appendicitis adherent to the liver capsule

Beklenmedik bir vaka: Karaciğer kapsülüne yapışık retroçekal apandisit

Hasan Börekci¹, Sinan Karacabey², Mesut Sipahi¹, Zeynep Tuğba Özdemir³, Mustafa Fatih Erkoç⁴

ABSTRACT

The cases of appendicitis take an important place in the hospital emergency departments and it must be kept in mind in the differential diagnosis of patients presenting with abdominal pain. Related to cecum, the appendix can be found in many different positions; however, it is mostly observed descending intraperitoneally (31–74%) and at the retrocecal region (26–65%). In this case report, we present the case of a 26-year-old female patient admitted to the emergency room with a colic pain in the right upper quadrant for about 2 days. Computed tomography revealed contamination in the fatty plans around the cecum and adhesive retrocecal appendicitis from the liver to the retroperitoneum. Appendectomy was performed. The pathology result was gangrenous appendicitis. In the literature, there is no similar case of appendicitis with hepatic adhesions. In conclusion, we want to emphasize that physicians and surgeons in the emergency departments must be more careful during the differential diagnosis of a patient with appendicitis and atypical symptoms and a more detailed investigation is required.

Keywords: Appendicitis, retrocecal appendix, liver capsule

ÖZET

Apandisit vakaları hastane acil servislerinde önemli bir yer tutmakta olup karın ağrısı ile başvuran hastalarda ayırıcı tanı açısından da göz önünde bulundurulması gerekmektedir. Apendiks çekumla ilişkili olarak birçok farklı pozisyonunda bulunabilir. En sık intraperitoneal desending (%31-74) ve retroçekal (%26-65) olarak görülmektedir. Bizim vakamız 26 yaşında kadın hasta acil servise iki gündür devam eden kolik vasıfta sağ üst kadranda ağrısı nedeniyle getirildi. Tomografide çekum etrafındaki yağlı planlarda heterojenite ve karaciğere retroperitondan yapışan retroçekal apandisit izlendi ve apendektomi yapıldı. Yaptığımız literatür incelemesinde hepatik yapışıklık olan bir apandisit olgusuna rastlamadık. Sonuç olarak belirtmek isteriz ki acil servislerde görevli hekim ve cerrah arkadaşlarımız bu olgu sunumunda belirtildiği gibi atipik bulgulara sahip bir apandisit hastasıyla karşılaşabilir. Bunun için de ayırıcı tanıyla teşhisin daha detaylı konulmaya çalışılması oldukça önemlidir.

Anahtar Kelimeler: Apandisit, retroçekal apendiks, karaciğer kapsülü

INTRODUCTION

Appendicitis cases play an important role in hospital emergencies and should be considered in the differential diagnosis of patients with abdominal pain (1). If the appendicitis cannot be diagnosed and the patients leave the hospital with another diagnosis, clinical complications such as appendix perforation or plastron state of intra-abdominal abscess can develop (2). The cecum appendix can be found in many different positions, particularly descending intraperitoneally (31–74%) and at the retrocecal region (26–65%). According to the location of the appendix, patients can be admitted with a different history and physical examination findings can also be different. One of them is an infection in the retrocecal appendix (3). Retrocecal appendicitis may present with different clinical symptoms. Due to the location of the retrocecal appendix, right lower quadrant tenderness may not be observed. Therefore, there could be difficulties in the diagnosis (4).

In half of the retrocecal appendicitis cases, atypical clinical symptoms can be observed (5). In this case, the appendix was in the retrocecal region and physical examination was obviously positive in the right upper quadrant. Right upper quadrant pain can rule out the diagnosis of appendicitis, and mostly suggests cholecystitis, gastritis, duodenal ulcer, and other liver or gallbladder pathologies; therefore, we wanted to present this unusual case in detail. In retrocecal appendicitis cases, the pararenal abscess can be observed added to the appendicitis or infection can also spread to the right paracolic space, right subphrenic, and subhepatic area (6, 7). If our case had a diagnosis other than appendicitis, in the following days, a retroperitoneal abscess could have occurred.

There is no similar case report to ours in the literature and we wanted to highlight that appendicitis cases can present with different clinical symptoms and during the differential diagnosis of patients presenting with abdominal pain, it should be kept in mind.

CASE PRESENTATION

A 26-year-old female patient admitted to the emergency room with a colic pain in the right upper quadrant for about 2 days. In her history, there were only two pregnancies and two live births.

¹Department of General Surgery, Bozok University Faculty of Medicine, Yozgat, Turkey

²Department of Emergency, Bozok University Faculty of Medicine, Yozgat, Turkey

³Department of Internal Medicine, Bozok University Faculty of Medicine, Yozgat, Turkey

⁴Department of Radiology, Bozok University Faculty of Medicine, Yozgat, Turkey

Address for Correspondence Yazışma Adresi

Hasan Börekci

Bozok Üniversitesi Tıp Fakültesi,
Genel Cerrahi Anabilim Dalı,
Yozgat, Türkiye
Phone: +90 354 212 70 60
e-mail: hborekci@mynet.com

Received / Geliş Tarihi: 31.10.2014
Accepted / Kabul Tarihi: 25.01.2015
Available Online Date /
Çevrimiçi Yayın Tarihi: 14.07.2015

©Copyright 2015
by Turkish Surgical Association
Available online at
www.ulusalcerahidergisi.org

©Telif Hakkı 2015
Türk Cerrahi Derneği

Makale metnine
www.ulusalcerahidergisi.org
web sayfasından ulaşılabilir.

Vital parameters were as follows; blood pressure (BP): 110/70 mm-Hg, pulse: 86/min fever: 37.8°C.

In the physical examination; bowel sounds were normoactive with auscultation; there was tenderness in all abdominal regions and rebound in the right upper quadrant. No other findings were observed in the other systems. Acute cholecystitis was first diagnosed; blood tests and ultrasound (USG) were performed.

The results of the blood tests were as follows: WBC: 15800/mm³, Hgb: 13.6 g/dL, hematocrit: 39.8%, urea 11 mg/dL Cr: 0.64 mg/dL, AST: 12 IU/L, ALT: 12 IU/L, total bilirubin: 0.5 mg/dL, direct bilirubin: 0.3 mg/dL. USG showed normal gallbladder wall thickness and no calculi and no calculi or hydronephrosis in the kidneys.

Thus, the diagnosis of acute cholecystitis was excluded. In order to investigate the cause of pain in the abdomen, computed tomography (CT) was requested. CT revealed contamination in the fatty plans around the cecum and adhesive

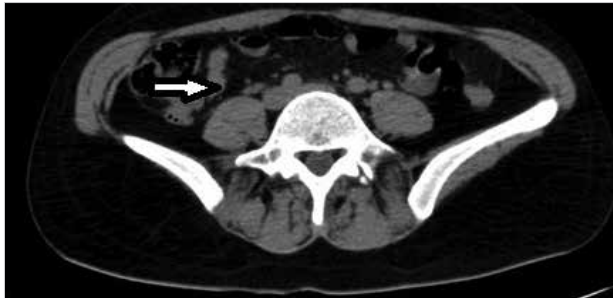

Figure 1. There is contamination in the fatty plans around the cecum

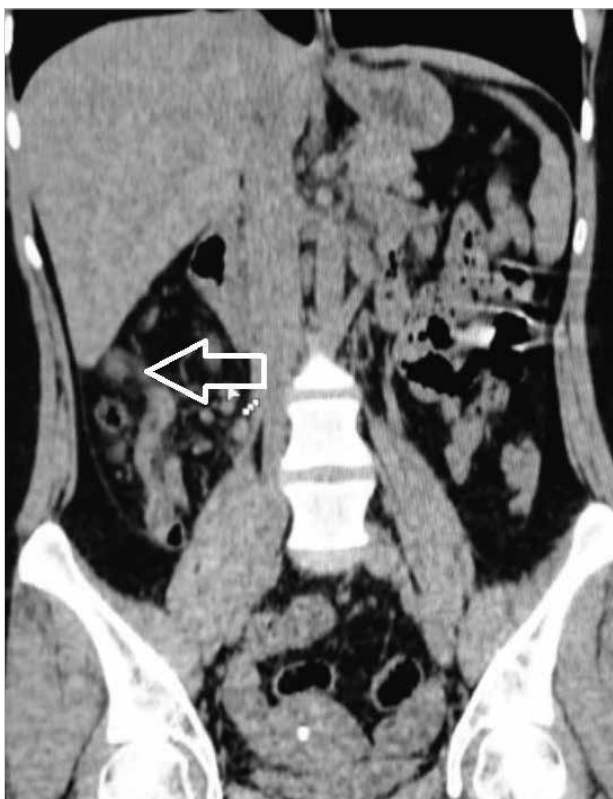


Figure 2. Appendix tissue extension into the liver

retrocecal appendicitis from the liver to the retroperitoneum. Contamination was also observed in the adipose tissue under the liver (Figure 1, 2).

After the general surgery consultation with the diagnosis of acute abdomen, the patient underwent surgery immediately. Appendectomy was performed with the right paramedian incision. The stump was buried and mesoplasty was performed. No other pathology was found in the abdomen. It was phlegmonous from the tip of the appendix and joined through retroperitoneum to the liver capsule (Figure 3). The pathology result revealed gangrenous appendicitis. Postoperatively, IV antibiotics and analgesics were started. She was mobilized the first day. She was discharged due to her well-being.

A signed written informed consent was taken from the patient.

DISCUSSION

Despite improvement in the techniques, the diagnosis of acute appendicitis remains challenging and the complications of the disease and the rate of negative laparotomy have not been reduced significantly (8). Complaints and symptoms may be atypical in patients with retrocecal appendicitis and can imitate right upper quadrant and right flank pathologies such as acute cholecystitis, renal colic, and diverticulitis (9). The location of the appendix can vary according to the position and shape of the cecum in organogenesis. The incidence of retrocecal appendix is 26–65% (10).

In this case, there was obviously tenderness, rebound, and defense in the right upper quadrant on physical examination. Moreover, she had anorexia and sometimes nausea complaints

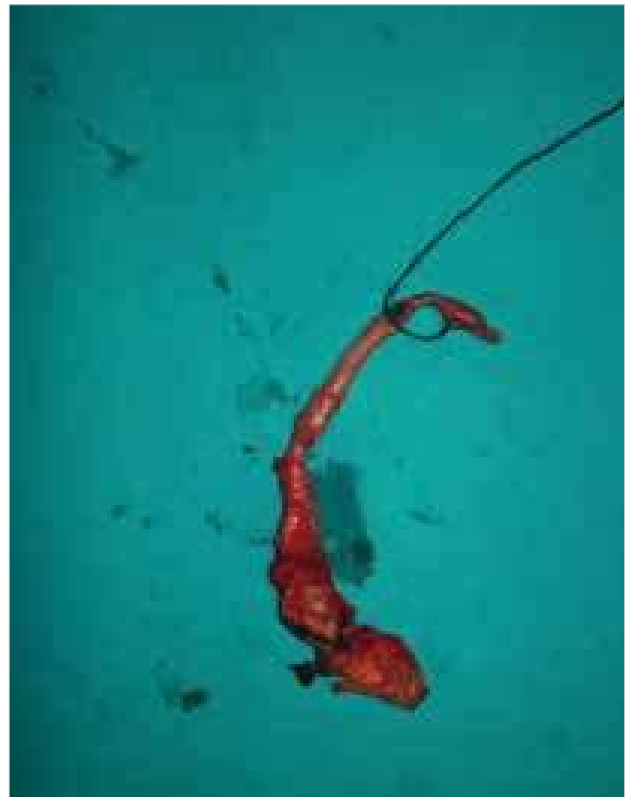

Figure 3. The phlegmonous end portion of the appendix tissue

in the last 2 days. In appendicitis, generally pain starts from the epigastric area; anorexia symptoms and the right lower quadrant pain occur in the next few days. Therefore, this case is atypical. Routine USG is used in the diagnosis as the first step. A study on children's cases showed that the appendicitis diagnosis rate is 99% in suspected cases (11). Another study showed that the use of USG in the suspected cases diminished the negative laparotomies and the morbidity rate because of a delay in diagnosis (12).

However, in adults, it is indicated that non-contrast CT is superior to USG and CT decreases the false laparotomy rates (13). When clinically, gallbladder, hepatobiliary, or urinary tract pathologies are suspected in patients in the emergency departments, USG is frequently performed. With this in mind, liver abscess and fluid collection in the subhepatic or the right flank region can be observed on ultrasonography in retrocecal appendicitis cases (11). However, in this case, no pathology was detected on USG and the diagnosis was confirmed by CT.

In the inflammatory process of retrocecal appendix, it can spread to the perirenal, adrenal, and subhepatic region (6). In our case, the appendix was attached to the liver tissue. In the literature, no cases of appendicitis with hepatic adhesions have been reported.

In this case, the cause of the right upper quadrant pain (presence of Murphy's sign) was the irritation of the liver fascia. Here we would like to emphasize again that further research should be performed by the physicians and surgeons in emergency rooms for the differential diagnosis of patients admitting with atypical symptoms. With wrong diagnosis and treatment, the patient's symptoms can become more complicated in the coming days and this can increase morbidity and mortality. We recommend that the use of additional imaging systems for the possible diagnoses without hesitation in patients with atypical signs is important. We first observed USG in our case and although we could not find any pathology, we required a non-contrast abdominal CT for the differential diagnosis. After CT, we were able to properly diagnose.

CONCLUSION

When acute appendicitis is not suspected clinically in patients with abdominal pain in the emergency departments; we need to remember that the physical examination findings can differ according to the localization of the appendix. As observed in this case, one can be faced with retrocecal appendicitis attached to the liver capsule. Furthermore, it should be kept in mind that retrocecal appendicitis can be complicated and an abscess can occur in the abdomen.

Informed Consent: Written informed consent was obtained from patient who participated in this case.

Peer-review: Externally peer-reviewed.

Author Contributions: Concept - H.B.; Design - H.B., Z.T.Ö.; Supervision - M.S., S.K.; Funding - H.B., Z.T.Ö.; Materials - H.B.; Data Collection and/

or Processing - H.B., S.K., M.S., M.F.E.; Analysis and/or Interpretation - H.B., M.S., M.F.E.; Literature Review - H.B., Z.T.Ö.; Writer - H.B., Z.T.Ö.; Critical Review - M.S., M.F.E.; Other - S.K.

Conflict of Interest: No conflict of interest was declared by the authors.

Financial Disclosure: The authors declared that this study has received no financial support.

Hasta Onamı: Yazılı hasta onamı bu olguya katılan hastadan alınmıştır.

Hakem Değerlendirmesi: Dış bağımsız.

Yazar Katkıları: Fikir - H.B.; Tasarım - H.B., Z.T.Ö.; Denetleme - M.S., S.K.; Kaynaklar - H.B., Z.T.Ö.; Malzemeler - H.B.; Veri toplanması ve/veya işlemesi - H.B., S.K., M.S., M.F.E.; Analiz ve/veya yorum - H.B., M.S., M.F.E.; Literatür taraması - H.B., Z.T.Ö.; Yazıyı yazan - H.B., Z.T.Ö.; Eleştirel İnceleme - M.S., M.F.E.; Diğer / Other - S.K.

Çıkar Çatışması: Yazarlar çıkar çatışması bildirmemişlerdir.

Finansal Destek: Yazarlar bu çalışma için finansal destek almadıklarını beyan etmişlerdir.

REFERENCES

1. Paulson EK, Kalady MF, Pappas TN. Clinical practice. Suspected appendicitis. *N Engl J Med* 2003; 348: 236-242. [\[CrossRef\]](#)
2. Bradley EL, 3rd, Isaacs J. Appendiceal abscess revisited. *Arch Surg* 1978; 113: 130-132. [\[CrossRef\]](#)
3. Wakeley CP. The position of the vermiform appendix as ascertained by an analysis of 10,000 cases. *J Anat* 1933; 67: 277-283.
4. Rasmussen OO, Hoffmann J. Assessment of the reliability of the symptoms and signs of acute appendicitis. *J R Coll Surg Edinb* 1991; 36: 372-377.
5. Lee SL, Ho HS. Acute appendicitis: is there a difference between children and adults? *Am Surg* 2006; 72: 409-413.
6. Meyers MA, Oliphant M. Ascending retrocecal appendicitis. *Radiology* 1974; 110: 295-299. [\[CrossRef\]](#)
7. Feldberg MA, Hendriks MJ, van Waes PF. Computed tomography in complicated acute appendicitis. *Gastrointest Radiol* 1985; 10: 289-295. [\[CrossRef\]](#)
8. Eryılmaz R, Alimoglu O, Bas G. Akut apandisitte tanı ve tedavide gecikme ve klinik sonuçları. *Ulus Cerrahi Derg* 2001; 17: 106-110.
9. Kim S, Lim HK, Lee JY, Lee J, Kim MJ, Lee AS. Ascending retrocecal appendicitis: clinical and computed tomographic findings. *J Comput Assist Tomogr* 2006; 30: 772-776. [\[CrossRef\]](#)
10. Rao PM, Rhea JT, Novelline RA, Mostafavi AA, Lawrason JN, McCabe CJ. Helical CT combined with contrast material administered only through the colon for imaging of suspected appendicitis. *AJR Am J Roentgenol* 1997; 169: 1275-1280. [\[CrossRef\]](#)
11. Lee JH, Jeong YK, Park KB, Park JK, Jeong AK, Hwang JC. Operator-dependent techniques for graded compression sonography to detect the appendix and diagnose acute appendicitis. *AJR Am J Roentgenol* 2005; 184: 91-97. [\[CrossRef\]](#)
12. Eryılmaz R, Baş G, Alimoglu O, Ercan M, Sahin M. Akut apandisit şüpheli hastalarda ultrasonografinin ayırıcı tanıda artan önemi. *Ulus Cerrahi Derg* 2001; 17: 28-33.
13. Basak M, Çolakoğlu B, Ozkurt H, Yetkin G. Akut apandisit kontrastsız spiral bilgisayarlı tomografi (BT) bulguları. *Ulus Cerrahi Derg* 2001; 17: 34-41.